Ultrasound Obstet Gynecol 2008; **32**: 220–225
Published online 10 July 2008 in Wiley InterScience (www.interscience.wiley.com). **DOI:** 10.1002/uog.5401

Triage for surgical management of ovarian tumors in asymptomatic women: assessment of an ultrasound-based scoring system

J. L. ALCÁZAR, P. ROYO, M. JURADO, J. Á. MÍNGUEZ, M. GARCÍA-MANERO, C. LAPARTE, R. GALVÁN and G. LÓPEZ-GARCÍA

Department of Obstetrics and Gynecology, Clinica Universitaria de Navarra, School of Medicine, University of Navarra, Pamplona, Spain

KEYWORDS: adnexal masses; surgery; triage; ultrasound

ABSTRACT

Objectives *To prospectively evaluate an ultrasound-based scoring system as a method for triaging asymptomatic women presenting with an adnexal mass for surgical treatment.*

Methods *Two hundred and four adnexal masses in 189 asymptomatic women undergoing elective surgical treatment at our institution were included in this prospective study. Patients were evaluated by transvaginal power Doppler ultrasound imaging before surgery. Patients were classified as low risk or high risk for malignancy according to an ultrasound-based scoring system. Women with a low risk for malignancy were scheduled for laparoscopy and patients with a high risk for malignancy were scheduled for laparotomy. However, patients classified as low risk by the ultrasound scoring system, but with a tumor size* ≥ 10 *cm or clinical suspicion of pelvic adhesions, were instead considered to be at intermediate risk and were scheduled for laparotomy. Some patients classified as high risk were scheduled for an operative laparoscopy by an expert in gynecological oncology.*

Results *One hundred and thirty-four (65.7%) masses were considered to be low risk and were treated by a laparoscopically guided procedure. All these tumors were benign. Forty-seven (23%) masses were classified as high risk, of which 39 tumors were malignant and eight benign. Twenty-three (11.3%) tumors were considered to be intermediate risk and were scheduled for primary laparotomy. In this group, 21 (91.3%) tumors proved to be benign and two (8.7%) were malignant.*

Conclusions *Ultrasound-based triage of asymptomatic women diagnosed with a persistent adnexal mass is effective for selecting the surgical approach. Copyright © 2008 ISUOG. Published by John Wiley & Sons, Ltd.*

INTRODUCTION

Women who present with pelvic masses commonly require surgical intervention. Most of these masses are benign. Laparoscopy has become the 'gold standard' in the surgical management of benign adnexal masses because this technique is associated with a lower morbidity and involves a shorter hospital stay than does laparotomy[1].

On the other hand, accurate surgical staging and cytoreductive surgery have been shown to be among the most important prognostic factors in ovarian cancer[2]. Furthermore, it has been demonstrated that better outcomes are achieved for ovarian cancer patients when a gynecological oncologist performs this surgery[3]. For these reasons, women presenting with suspicious adnexal masses should be referred for primary laparotomy to specialized centers for gynecological oncology with experienced surgeons and adequate resources.

However, many patients with ovarian cancer are still operated on in local non-specialized hospitals[4]. In many cases this occurs because of an inaccurate preoperative diagnosis. Therefore, an accurate preoperative diagnosis is essential in order to establish the optimal management in these patients.

Physical examination, serum CA 125 levels and ultrasound examination have been used conventionally for the differential diagnosis of adnexal masses. Physical examination has been shown to be of limited value, even under ideal conditions such as examination under general anesthesia[5]. The use of CA 125 has also been limited

Correspondence to: Dr J. L. Alcázar, Department of Obstetrics and Gynecology, Clinica Universitaria de Navarra, Avenida Pio XII 36, 31008 Pamplona, Spain (e-mail: jlalcazar@unav.es)

Accepted: 14 February 2008

because of its low positive predictive value (PPV) and low sensitivity for early stages of ovarian cancer[6].

Ultrasound imaging has been shown to be the best diagnostic tool for differentiating malignant from benign adnexal masses, with a sensitivity of around 90% and a false-positive rate of about 25%[7]. For this reason, ultrasound is considered as the first-line imaging technique to be used when assessing an adnexal mass[8].

In 2003 we published our ultrasound scoring system, based on morphological and Doppler assessment, for distinguishing between benign and malignant adnexal masses[9]. The aim of the present study was to prospectively evaluate this scoring system as a method for triaging women presenting with an adnexal mass for surgical treatment, laparoscopy or laparotomy.

METHODS

Over a 2-year period (June 2003 to June 2005), 189 asymptomatic women diagnosed with an adnexal mass and undergoing elective surgical treatment at our institution were included in this prospective study. Their mean age was 40.7 (range, 15–73) years. One hundred and forty-eight (78.3%) women were premenopausal and 41 (21.7%) were postmenopausal. Fifteen women had bilateral masses, giving a total of 204 masses evaluated. Our Institutional Review Board approved the study and all women gave informed consent.

All patients were evaluated within 1 week before surgery. Diagnostic work-up included a complete medical history, physical examination and ultrasound examination. Medical history focused especially on patients' complaints and past history that could raise the suspicion of presence of pelvic adhesions, such as pelvic inflammatory disease (PID), pelvic endometriosis, peritonitis or previous pelvic surgery.

Staff specialists in obstetrics and gynecology, three of them specialized in gynecological oncology (J.L.A., M.J., G.L.G.), performed physical examinations in all cases. Findings were reported as 'inconclusive' when no reliable information could be obtained; 'non-suspicious for malignancy' in the presence of an adnexal mass with a maximum diameter of less than 8 cm, mobile at examination, of cystic or solid consistency but with regular contours and no evidence of ascites; or 'suspicious for malignancy' in the presence of at least one of the following: fixed and/or irregular adnexal mass regardless of the size, maximum diameter > 8 cm and evidence of ascites. Pelvic adhesions were suspected in the case of a non-mobile mass that was fixed to the uterus or cul-de-sac, and a past medical history of PID, pelvic endometriosis, peritonitis or previous pelvic surgery.

The uterus and adnexal regions of all patients were examined by transvaginal power Doppler ultrasonography using a Voluson 730 (GE Healthcare Technologies, Milwaukee, WI, USA). Special attention was paid to adnexal masses. First, tumor size was calculated according to maximum diameter. Then, morphological evaluation was performed with attention to the following parameters[10]: bilaterality, wall thickness (thin < 3 mm, thick ≥ 3 mm), septations (not present, thin < 3 mm, thick ≥ 3 mm), papillary projections (not present, thin < 3 mm in length, thick ≥ 3 mm in length), solid areas (not present, presence of any solid area $\geq 1 \times 1$ cm in internal wall surface or septum) and ultrasound appearance (cystic, anechogenic, homogeneous content, heterogeneous content or mostly solid).

Following morphological evaluation, color Doppler imaging was performed to identify vascular color signals within the tumor. If blood flow was detected it was reported as peripheral (color signals in the tumor wall or periphery of a solid tumor) or central (blood flow detected in septa, papillary projections, solid areas or central part of a solid tumor). In tumors with both peripheral and central blood flow, only central blood flow was used for analysis.

Once a vessel had been identified by color Doppler imaging, pulsed Doppler was used to obtain a flow velocity waveform (FVW). Resistance index ($RI = [S - D]/S$, where S and D are mean systolic and diastolic velocities) and peak systolic velocity (PSV, cm/s) were automatically calculated from at least three consecutive FVWs. In those tumors with more than one vessel the lowest RI and highest PSV found were used for analysis. Tumors were classified into four velocimetric categories[11]: low velocity/low resistance (PSV < 10 cm/s, RI ≤ 0.45), low velocity/high resistance (PSV < 10 cm/s, RI > 0.45), high velocity/high resistance (PSV ≥ 10 cm/s, RI > 0.45) or high velocity/low resistance (PSV ≥ 10 cm/s, RI ≤ 0.45). All premenopausal women were evaluated in the follicular phase of the menstrual cycle.

We applied our scoring system[9] to the findings (Table 1). A score of ≥ 6 was considered to be suspicious for malignancy. Patients were managed according to the following protocol (Figure 1). Patients with adnexal masses with a score < 6 and < 10 cm in size were considered to be at low risk for malignancy and were scheduled for laparoscopic surgery. Patients with adnexal masses with a score < 6, but with a maximum tumor diameter ≥ 10 cm and/or suspicion of pelvic adhesions, were considered to be at intermediate risk for cancer, and were scheduled for laparotomy. Patients with adnexal masses with an ultrasound score ≥ 6 were considered to be at high risk for cancer and were scheduled for laparotomy. In this group an abdominal ultrasound or computed

Table 1 Ultrasound-based scoring system for classification of ovarian tumors

Score	*Thick papillary projections*	*Solid areas*	*Blood flow location*	*Doppler velocimetry*
0	No	No	No flow or peripheral	No flow/other
2	Yes	—	—	High velocity/low resistance
4	—	Yes	Central	—

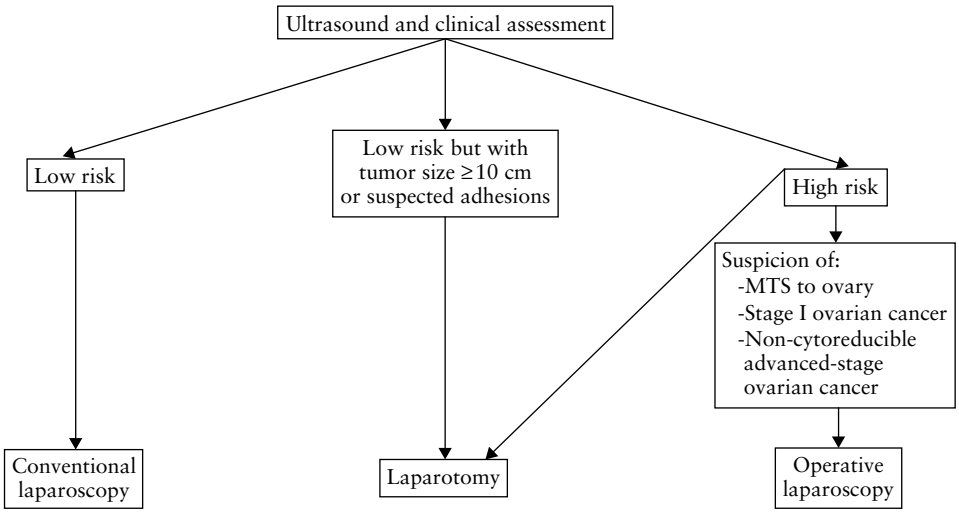

Figure 1 Flow chart showing ultrasound-based triage for selecting surgical approach. MTS, metastasis.

tomography scan was performed in order to evaluate the spread of disease. Some selected cases in this group (with suspicion of metastases to the ovary, suspicion of non-cytoreducible advanced-stage ovarian cancer, or suspicion of small-sized early ovarian cancer) were ultimately scheduled for advanced operative laparoscopy by an expert in gynecological oncology.

In all cases tumors were surgically removed by trained surgeons with more than 7 years' experience in laparoscopic surgery (J.L.A., M.J., G.L.G., J.A.M., M.G.M.), as well as more than 10 years' experience in gynecological oncological surgery (J.L.A., M.J., G.L.G.), and definitive histological diagnoses were obtained. Tumors were classified according to the World Health Organization classification[12]. Ovarian malignancies were staged according to the FIGO classification[13]. Tumors of low malignant potential were considered to be malignant.

Qualitative variables were described as percentages and compared using the Chi-square test. Continuous variables were presented as median with range and compared using the Mann–Whitney *U*-test. Sensitivity, specificity, PPV, negative predictive value (NPV) and accuracy were calculated for physical examination and the scoring system. The McNemar test was used for comparing sensitivity and specificity. $P < 0.05$ was considered statistically significant. SPSS version 15.0 for Windows (SPSS, Chicago, IL, USA) was used for statistical analysis.

RESULTS

Findings were considered suspicious for malignancy on physical examination in 31 cases (15.2%). The ultrasound score was ≥ 6 in 25 (81%) of these 31 cases.

After ultrasound examination, 134 (65.7%) masses in 123 women were considered to be low-risk tumors and were scheduled for laparoscopy. In two of these women laparoscopy was converted to laparotomy because of pelvic adhesions. All tumors in this group proved to be benign.

Twenty-three (11.3%) masses with an ultrasound score of < 6 were considered to be intermediate-risk tumors and were scheduled for primary laparotomy owing to their large size (≥ 10 cm; $n = 15$, 65.2%) or suspicion of pelvic adhesions ($n = 8$, 34.8%). In this group, 21 (91.3%) tumors were benign and two (8.7%) were malignant (one Stage III ovarian cancer and one adenocarcinoma of the appendix with metastases to the right ovary). Both malignant tumors were large with no evidence of metastatic disease and an ultrasound score < 6 because of the absence of blood flow. These results are summarized in Figure 2.

Forty-seven (23%) masses in 43 women were considered to be high-risk tumors. In this group, 31 (72.1%) patients (34 masses) were scheduled for primary laparotomy. Thirty-three (97%) of these tumors were malignant and one (3%) was benign (endometrioma). Twelve (27.9%) women (13 masses) were scheduled for advanced oncological laparoscopy because of suspicion of metastases to the ovary ($n = 2$, 16.7%), non-cytoreducible advanced ovarian cancer ($n = 3$, 25%) and early-stage ovarian cancer ($n = 7$, 58.3%). Six (46.1%) of these 13 tumors were ultimately confirmed histologically as malignant and seven (53.9%) were benign lesions (four cystadenofibromas, one tubo-ovarian abscess, one dermoid and one Brenner tumor).

The correlation between risk group and final histology is shown in Table 2. Ultrasound features according to risk group are shown in Table 3. Median tumor size in low-, intermediate- and high-risk groups was 49 (range, 10–98) mm, 110 (range, 40–238) mm and 72 (range, 21–270) mm, respectively. Median tumor size was significantly greater in the intermediate-risk than in the low-risk group ($P = 0.0001$), and in the high-risk compared with the low-risk group ($P = 0.004$). No significant difference was found between the intermediate- and high-risk groups.

Physical examination was able to detect 76% of cases of advanced ovarian cancer (19/25). However, it detected only 4/10 cases of early-stage ovarian cancer and 2/6 cases of metastatic cancer to the ovary. In benign tumors, the

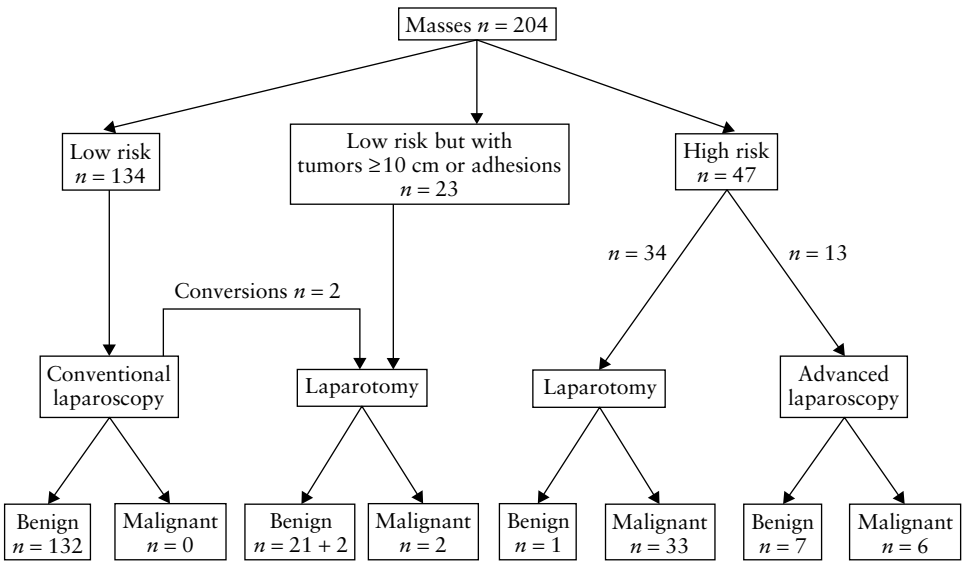

Figure 2 Flow chart showing management of patients according to our ultrasound-based and clinical triage.

Table 2 Histology of the tumors according to risk classification

Tumor type	*Low risk* (n)	*Intermediate risk* (n)	*High risk* (n)
Ovarian cancer Stage I	0	0	4
Ovarian cancer Stage II–IV	0	1	21
Low malignant potential tumor	0	0	8
Metastatic tumor	0	1	6
Endometrioma	56	4	1
Dermoid cyst	18	4	1
Serous cystadenoma	25	2	0
Mucinous cystadenoma	7	4	0
Hemorrhagic cyst	8	1	0
Hydrosalpinx	4	2	0
Cystadenofibroma	3	1	4
Tubo-ovarian abscess	0	0	1
Other benign tumor	13	3	1*
Total	134	23	47

Low risk: score < 6, maximum tumor diameter < 10 cm, no suspicion of pelvic adhesions. Intermediate risk: score < 6 with maximum tumor diameter ≥ 10 cm or suspicion of pelvic adhesions. High risk: score ≥ 6. *One Brenner tumor.

findings on physical examination were non-suspicious in 157 (96%) cases. In six (3.7%) cases of benign tumor, findings on physical examination were suspicious for malignancy.

The sensitivity, specificity, PPV, NPV and accuracy of physical examination in identifying malignant tumors were 61%, 96%, 81%, 91% and 89%, respectively. The positive likelihood ratio (LR+) for malignancy of suspicious findings on physical examination was 16.7 (95% CI, 7.3–37.7) and the negative likelihood ratio (LR−) was 0.41 (95% CI, 0.28–0.59).

Our ultrasound-based scoring system was able to detect 100% of early ovarian cancers, 96% of advanced ovarian cancers and 87.5% of metastatic cancers to the ovary. The sensitivity, specificity, PPV, NPV and accuracy of our ultrasound-based scoring system were 95%, 95%, 83%, 99% and 95%, respectively. The LR+ for malignancy of an ultrasound score ≥ 6 was 19.4 (95% CI, 9.8–38.2) and the LR− was 0.05 (95% CI, 0.01–0.20). The scoring system was significantly more sensitive than physical examination (McNemar test, $P = 0.004$). No statistical differences were found in specificity.

DISCUSSION

An accurate preoperative evaluation of adnexal masses is essential in order to establish the optimal management and appropriate referral of patients diagnosed with these lesions. Physical examination has been shown to be of limited value in detecting ovarian cancer, especially when tumors are small or the patient obese[5]. Our results confirm these data.

The differential diagnosis of adnexal masses has largely relied on the use of ultrasound examination. The basis of this technique is morphological characterization of the tumor[7]. The role of pulsed Doppler imaging remains controversial[14]. Some authors have advocated the use of vessel location for reducing the false-positive rate of B-mode morphological evaluation, with encouraging results[15].

A Medline search (1966–2006) identified only two papers proposing and prospectively evaluating a protocol for providing the best surgical approach for women diagnosed with an adnexal mass. Berlanda *et al.* used a complex algorithm based on a scoring system for B-mode morphological characterization of the adnexal mass[16]. If the score was < 9 patients were considered to be at low risk, and scheduled for laparoscopy. In masses with a score ≥ 9, other factors, such as size ≥ 10 cm, mobility, bilaterality, presence of ascites, serum CA 125 level ≥ 35 IU/mL and an intraovarian artery resistance index ≤ 0.6, were taken into account. If at least one of these features was present then the mass was considered to be high risk and scheduled for laparotomy; those

Table 3 Sonographic features of the tumors according to risk classification

Feature	*Low risk* (n = *134*)	*Intermediate risk* (n = *23*)	*High risk* (n = *47*)	P
Cyst wall				< 0.001
Thin	124 (92.5)	15 (65.2)	18 (38.3)	
Thick	10 (7.5)	8 (34.8)	29 (61.7)	
Papillary projections				< 0.001
None	123 (91.8)	21 (91.3)	20 (42.6)	
Thin	5 (3.7)	1 (4.3)	0 (0)	
Thick	6 (4.5)	1 (4.3)	27 (57.4)	
Septations				< 0.001
None	112 (83.6)	19 (82.6)	30 (63.9)	
Thin	19 (14.2)	2 (8.7)	7 (14.9)	
Thick	3 (2.2)	2 (8.7)	10 (21.3)	
Solid areas				< 0.001
None	115 (85.8)	15 (65.2)	12 (25.5)	
Present	19 (14.2)	8 (34.8)	35 (74.5)	
Echogenicity				< 0.001
Cystic	110 (82.1)	13 (56.6)	2 (4.3)	
Cystic–solid	19 (14.2)	5 (21.7)	28 (59.6)	
Mostly solid	5 (3.7)	5 (21.7)	17 (36.2)	
Blood flow				< 0.001
None	59 (44)	7 (30.4)	2 (4.3)	
Peripheral	71 (53)	13 (56.6)	2 (4.3)	
Central	4 (3)*	3 (13)	43 (91.5)	
Velocimetry				< 0.001
Low velocity/high resistance	20 (26.7)	3 (18.8)	2 (4.4)	
Low velocity/low resistance	9 (12)	5 (31.2)	1 (2.2)	
High velocity/high resistance	42 (56)	7 (43.8)	12 (26.7)	
High velocity/low resistance	4 (5.3)	1 (6.2)	30 (66.7)	

Values are *n* (%). Low risk: score < 6, maximum tumor diameter < 10 cm, no suspicion of pelvic adhesions. Intermediate risk: score < 6 with maximum tumor diameter ≥ 10 cm or suspicion of pelvic adhesions. High risk: score ≥ 6. *Central flow present in septations, not in solid areas.

without any of these features were considered to be at moderate risk. This approach provided 90% sensitivity, 97% specificity, 82% PPV and 99% NPV, with an overall accuracy of 96%, in identifying malignant tumors as high risk. The odds of malignancy in high-, moderate- and low-risk groups were 4.5, 0.06 and 0.01, respectively.

Guerriero *et al.* proposed a simpler approach based on a first-step B-mode morphological ultrasound evaluation[17]. If the mass showed 'typical benign findings' such as dermoid, endometrioma or serous cyst, women were considered to be at very low risk and scheduled for laparoscopy. In cases of evidence of metastatic disease, large tumors (≥ 9 cm), presence of solid areas or ascites, patients were considered to be at very high risk and scheduled for laparotomy. Sensitivity, specificity, PPV and NPV for this protocol were 100%, 91%, 95% and 100%, respectively. The odds of malignancy in the very high-risk group were 3.55.

In our study, we propose an easy single-step ultrasound-based protocol for triaging asymptomatic patients diagnosed with adnexal mass for laparoscopy or laparotomy. Our protocol is based mainly on our morphological and color Doppler ultrasound scoring system. As in previous studies, our intention was to classify patients into low- and high-risk groups in order to select the most appropriate surgical approach. We also took tumor size and suspicion of pelvic adhesions into account in the low-risk group. These two issues may limit laparoscopic surgery. There is no established cut-off for tumor size when choosing between laparoscopy and laparotomy, although a maximum diameter of 10 cm seems to be a reasonable limit[18]. On the other hand, it should be borne in mind that the larger the tumor is the less accurate ultrasound examination of the whole lesion might be.

Our scoring system provided good results, giving a sensitivity, specificity, PPV, NPV and accuracy of 95%, 95%, 83%, 99% and 95%, respectively. These figures are similar to those obtained by Berlanda *et al.*[16] and Guerriero *et al.*[17], confirming that ultrasound-based triage is an excellent method of selecting the surgical approach for adnexal masses.

Bearing in mind that no protocol provides 100% accuracy, when the tumor was < 10 cm in maximum diameter and the ultrasound score was < 6 in our study, no malignancy was found on laparoscopic surgery. However, when tumor size was ≥ 10 cm, two malignant tumors were misclassified by our ultrasound scoring system as benign (of 23 such cases in our series). This highlights the limitations of an accurate ultrasound evaluation of large tumors and implies that these tumors should be

considered with caution. Similar conclusions were drawn by Guerriero *et al.*[17].

In spite of our efforts to achieve as accurate a preoperative diagnosis as possible, some benign tumors are still very difficult to discriminate from malignant lesions. Our scoring system produced a 5% false-positive rate in this prospective study. This figure lies between the 3% previously reported by Berlanda *et al.*[16] and 9% reported by Guerriero *et al.*[17]. This implies that, when using B-mode and Doppler ultrasound triage, an approximate false-positive rate of at least 5–10% has to be assumed in discriminating benign from malignant adnexal masses, even in experienced hands. In fact, the results of the largest multicenter study applying an ultrasound-based scoring system published so far reported a false-positive rate of 24%[18].

In conclusion, ultrasound-based triage of asymptomatic women diagnosed with an adnexal mass is effective for providing the most appropriate surgical approach, permitting treatment of most benign tumors by a laparoscopically guided procedure.

REFERENCES

1. Canis M, Rabischong B, Houlle C, Botchorishvili R, Jardon K, Safi A, Wattiez A, Mage G, Pouly JL, Bruhat MA. Laparoscopic management of adnexal masses: a gold standard? *Curr Opin Obstet Gynecol* 2002; **14**: 423–428.
2. Levin L, Lund B, Heintz AP. Advanced ovarian cancer. An overview of multi-variate analyses of prognostic variables with special reference to the role of cytoreductive surgery. *Ann Oncol* 1993; **4**: 23–29.
3. Engelen MJ, Kos HE, Willemse PH, Aalders JG, de Vires EG, Shaapveld M, Otter R, van der Zee Ag. Surgery by consultant gynecologic oncologists improves survival in patients with ovarian carcinoma. *Cancer* 2006; **106**: 589–598.
4. Carney ME, Lancaster JM, Ford C, Tsudikov A, Wiggins CL. A population-based study of patterns of care for ovarian cancer: who is seen by a gynecologic oncologist and who is not? *Gynecol Oncol* 2002; **84**: 36–42.
5. Padilla LA, Radosevich DM, Milad MP. Limitations of the pelvic examination for evaluation of the female pelvic organs. *Int J Gynaecol Obstet* 2005; **88**: 84–88.
6. van Nagell JR Jr, Gallion HH, Pavlik EJ, DePriest PD. Ovarian cancer screening. *Cancer* 1995; **76**: 2086–2091.
7. Kinkel K, Hricak H, Lu Y, Tsuda K, Filly RA. US characterization of ovarian masses: a meta-analysis. *Radiology* 2000; **217**: 803–811.
8. Mettler L. The cystic adnexal mass: patient selection, surgical techniques and long-term follow-up. *Curr Opin Obstet Gynecol* 2001; **13**: 389–397.
9. Alcazar JL, Merce LT, Laparte C, Jurado M, López-García G. A new scoring system to differentiate benign from malignant adnexal masses. *Am J Obstet Gynecol* 2003; **188**: 685–692.
10. Timmerman D, Valentin L, Bourne TH, Collins WP, Verrelst H, Vergote I. Terms, definitions and measurements to describe the sonographic features of adnexal tumors: a consensus opinion from the International Ovarian Tumor Analysis (IOTA) Group. *Ultrasound Obstet Gynecol* 2000; **16**: 500–505.
11. Alcázar JL, Ruiz-Pérez ML, Errasti T. Transvaginal color Doppler sonography in adnexal masses: which parameter performs best? *Ultrasound Obstet Gynecol* 1996; **8**: 114–119.
12. Serov SF, Scully RE, Sobin LH. *International histological classification of tumors. Number 9, Histological typing of ovarian tumors*. World Health Organization: Geneva, 1973.
13. Sheperd JH. Revised FIGO staging for gynecological cancer. *Br J Obstet Gynaecol* 1989; **96**: 889–892.
14. Tekay A, Jouppila P. Controversies in assessment of ovarian tumors with transvaginal color Doppler ultrasound. *Acta Obstet Gynecol Scand* 1996; **75**: 316–329.
15. Guerriero S, Alcazar JL, Coccia ME, Ajossa S, Scarselli G, Boi M, Gerada M, Melis GB. Complex pelvic mass as a target of evaluation of vessel distribution by color Doppler sonography for the diagnosis of adnexal malignancies: results of a multicenter European study. *J Ultrasound Med* 2002; **21**: 1105–1111.
16. Berlanda N, Ferrari MM, Mezzopane R, Boero V, Grijuela B, Ferrazzi E, Pardi G. Impact of a multiparameter, ultrasound-based triage on surgical management of adnexal masses. *Ultrasound Obstet Gynecol* 2002; **20**: 181–185.
17. Guerriero S, Ajossa S, Garau N, Piras B, Paoletti AM, Melis GB. Ultrasonography and color Doppler-based triage for adnexal masses to provide the most appropriate surgical approach. *Am J Obstet Gynecol* 2005; **192**: 401–406.
18. Timmerman D, Testa AC, Bourne T, Ferrazzi E, Ameye L, Konstantinovic ML, van Calster B, Collins WP, Vergote I, van Huffel S, Valentin L. Logistic regression model to distinguish between the benign and malignant adnexal mass before surgery: a multicenter study by the International Ovarian Tumor Analysis Group. *J Clin Oncol* 2005; **23**: 8794–8801.

