

Congenital absence of the pedicles and the neural arch of L2

C. Villas
R. H. Barrios

Corresponde: C. Villas & R. H. Barrios Department of Orthopaedic Surgery and Traumatology University Clinic, School of Medicine, University of Navarre Avda. Pío XII s/n, E-31080 Pamplona, Spain Fax +34-948-17 22 94

ABSTRACT

Congenital pedicle abnormalities are rare. Unilateral aplastic and hypoplastic lumbar pedicles have been reported, but these were usually discovered incidentally and did not need surgical treatment. We present a case of absence of both pedicles and the neural arch of L2, with associated kyphoscoliosis with neurological involvement, which needed a two-stage corrective surgery. An L1-L4 fusion was achieved with relief of the symptoms.

KEY WORDS

Lumbar spine; Spine abnormalities; Lumbar fusion; Kyphosis; Scoliosis

INTRODUCTION

Congenital aplastic or hypoplastic defects of the pedicles and the neural arch are rare findings thought to represent varying degrees of the same anomaly [10]. Most reports present unilateral involvement of the cervical [7, 11, 16, 19] and lumbosacral spine [1, 2, 4-6, 8, 12, 14, 17, 20, 21] and, more rarely, of the thoracic spine [3, 18]. These patients, in most cases, had no neurological impairment and received either conservative treatment or none at all. We present a case of agenesis of both pedicles and the neural arch of L2, associated with kyphoscoliosis and neurological involvement that needed surgical correction.

CASE REPORT

A 23-year-old white male presented with a 3-year history of lumbar pain, lumbar prominence, paraesthesia on the anterior aspect of his right thigh and bilateral weakness. Physical examination revealed a lumbar kyphoscoliosis and bilateral hyperreflexia. No other abnormalities were detected. Plain radiographs showed an absence of both pedicles and the neural arch of L2, angular kyphosis, retro and lateral L2 listhesis and tilting of L2 and L3 (Fig. 1). Myelography demonstrated compression of the dural sac at the upper border of L2 in the sagittal plane — where the vertebral body had a postero-superior sharp angle pushing the spinal cord — and at the L3-L4 level in the coronal plane (Fig. 2). The CT scan confirmed the absence of the posterior structures of the vertebra (Fig. 3). Routine laboratory examinations gave normal results. Ultrasonic examination of the genitourinary system showed no abnormalities. The patient was operated initially by a posterior approach and a Dick fixator was used for the correction of the kyphoscoliosis. Peroperatively, fibrous tissue was found in the defect. Fifteen days later, by an anterior approach, an L1-L4 arthrodesis was performed using autologous fibular strut graft, without complications. Five years later the patient is asymptomatic and a solid L1-L4 fusion has been achieved (Fig. 4).

DISCUSSION

Congenital abnormalities of the pedicle are rare. In 1951, Roche and Rowe [13] studied the lumbosacral vertebrae of 4200 skeletons and found no pedicle abnormalities. In 1939, Hips [4] presented a case of an abnormal ossicle adjacent to the inferior portion of the right inferior articular facet of L3 discovered peroperatively. Later, Sicard, in 1959, cited three cases of congenital unilateral absence of a lumbar articular facet [15]. By 1975, only 17 cases of articular facet absence had been published in the literature [2]. Recently, Polly and Mason reported four cases of unilateral pedicle absence associated with back pain in children [12].

Developmental abnormalities of the pedicle include (a) persistent neurocentral synchondrosis, (b) cleft pedicle, (c) hypoplasia of the pedicle and (d) complete or partial agenesis of the pedicle and neural arch. These abnormalities represent failures in the three stages of the vertebral bodies' embryology: the membranous, cartilaginous and ossific stages [12, 18]. The association of a butterfly vertebra with the absent lumbar pedicle suggests developmental failure during the embryonic period, especially, chondrification [21].

According to Wortzman and Steinhardt [20], the terms “hypoplastic” and “absent” pedicle have been used synonymously with resultant confusion, and many cases reported as an “absent pedicle” were actually an aberrant hypoplastic pedicle. They believe that complete agenesis of the lumbar pedicle is quite a rare anomaly. In the cases previously reported [1, 2, 4-6, 8, 12, 14, 17, 20, 21] there was only unilateral involvement, no neurological impairment was observed and most of the patients needed only symptomatic treatment. In our case the extension of the defect was wide, with a complete absence of all L2 posterior structures leading to a discal hypermotility-instability, which resulted in a physiological retroposition at the upper zone of the lumbar lordosis, inducing a secondary kyphoscoliotic deformity with neurological involvement.

Radiologically, these anomalies were documented initially on plain radiographs, later on tomograms and more recently on CT and MR scans [2, 3, 8, 12, 19]. On the plain radiographs findings such as hypertrophy of the contralateral pedicle, displacement of the spinous process, and/or anomalies of the articular process were of great assistance in differentiating such anomalies from lytic lesions [8, 19]. Some authors indicate that MR with multiplanar imaging is superior to isolated axial CT studies in the evaluation of these types of anomalies and it also eliminates the need for further work-up to diagnose possible neoplastic or inflammatory lesions, which are included in the differential conventional radiographic diagnosis [14].

The treatment of this deformity is surgical [9]. The use of the Dick fixator facilitated the correction of the kyphoscoliosis allowing early ambulation of the patient. As reported by others in the cervical spine, fibrous tissue was found in the defect. [15, 18]. If a fusion is achieved the result is satisfactory, as in this case.

REFERENCES

1. Bardsley JL, Hanelin LG (1971) The unilateral hypoplastic pedicle. *Radiology* 101:315-317
2. Cotrel Y, Banai M (1976) Absence congénitale des facettes articulaires lombaires. A propos de deux cas. *Rev Chir Orthop* 62:731-736
3. Downey EF Jr, Whiddon SM, Brower AC (1986) Computed tomography of congenital absence of posterior element in the thoracolumbar spine. *Spine* 11:68-71
4. Hips HE (1939) Fissure formation in articular facets of the lumbar spine. *J Bone Joint Surg* 21 :289
5. Klinghoffer MD, Moroton G, Murdock MD, Mortimer B, Hermel MD (1975) Congenital absence of lumbar articular facets. *Clin Orthop* 106:
6. MacLeod S, Hendy GMA (1982) A congenital absence of a lumbar pedicle. A case report and a review of the literature. *Pediatr Radiol* 12:207-210
7. McLoughlin DP, Wortzman G (1972) Congenital absence of a cervical vertebral pedicle. *J Can Assoc Radiol* 23: 195-200
8. Mizutani M, Yamamuro T, Shikata J (1989) Congenital absence of a lumbar pedicle. *Spine* 14:890-891
9. Montgomery SP, Hall JE (1982) Congenital kyphosis. *Spine* 7 :360-364
10. Morin ME, Palacios E (1974) The aplastic hypoplastic lumbar pedicle. *AM J Roentgenol Radium Ther Nucl Med* 122:639-642
11. Oestreich AE, Young LW (1969) The absent cervical pedicle syndrome: a case in childhood. *Am J Roentgenol* 107:505-510
12. Polly DW Jr, Mason DE (1991) Congenital absence of a lumbar pedicle presenting as back pain in children. *J Pediatr Orthop* 11 :214-219
13. Roche MB, Rowe GG (1951) Incidence of separate neural arch and coincident bone variations: summary. *J Bone Joint Surg Am* 34:491-494
14. Sener RN, Ripeckyj GT, Jinkins JR (1991) Agenesis of a lumbar pedicle: MR demonstration. *Neuroradiology* 33:464
15. Sicard A (1959) *Chirurgie du rachis*. Masson, Paris
16. Steinbach HL, Boldrey EB, Sooy FA (1952) Congenital absence of the pedicle and superior facet from a cervical vertebra. *Radiology* 59 :838-840

17. Stelling CB (1981) Anomalous attachment of the transverse process to the vertebral body. An accessory finding in congenital absence of a lumbar pedicle. *Skeletal Radiol* 6:47-50
18. Tomsick TA, Lebowitz ME, Campbell C (1974) The congenital absence of pedicles in the thoracic spine. Report of two cases. *Radiology* 111 :587-589
19. Wilson CB, Norrell HA Jr (1966) Congenital absence of a pedicle in the cervical spine. *Am J Roentgenol* 97 : 639-647
20. Wortzman G, Steinhardt M (1984) Congenitally absent lumbar pedicle: a reappraisal. *Radiology* 152:713-718
21. Yousefzadeh DK, El-Khoury GY, Lupetin AR (1982) Congenital aplastic-hypoplastic lumbar pedicle in infants and young children. *Skeletal Radiol* 7 : 259-265

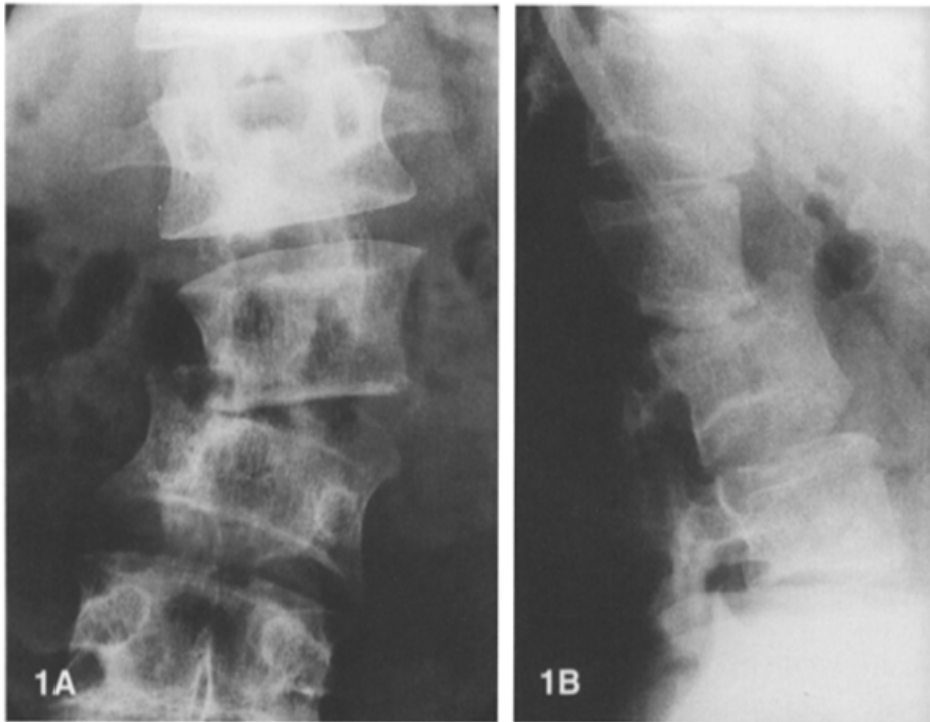


Figure 1. A. Plain radiograph showing absence of the pedicles of L2 and scoliosis.
B. Lateral view showing absence of the posterior structures of L2 and kyphosis.

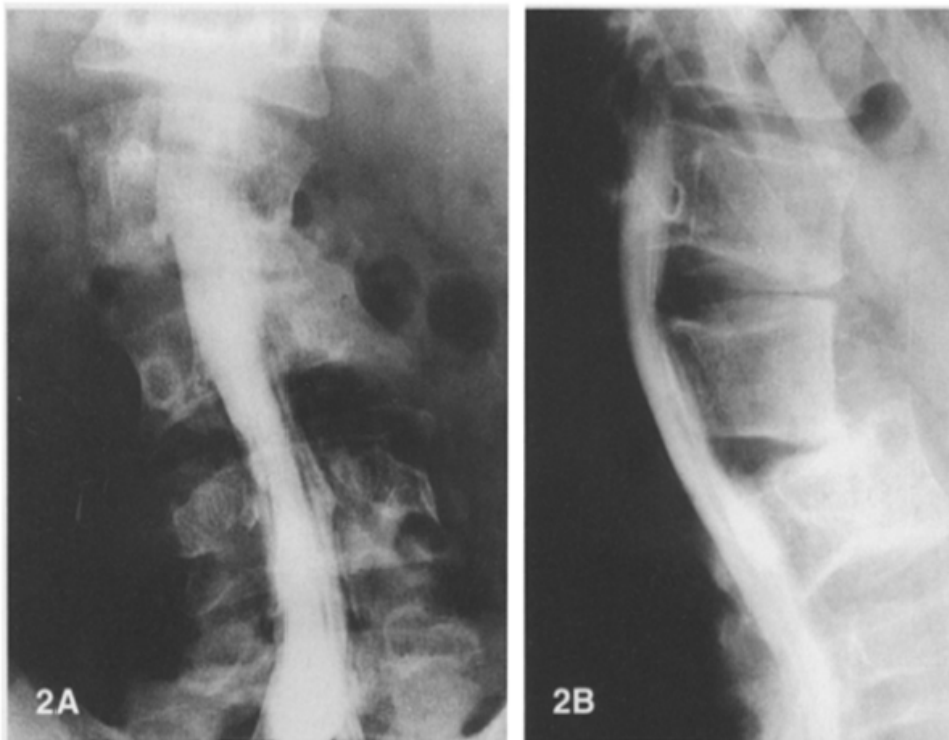


Figure 2 A. B. Anteroposterior (AP) and lateral myelography demonstrating compression of the dural sac.

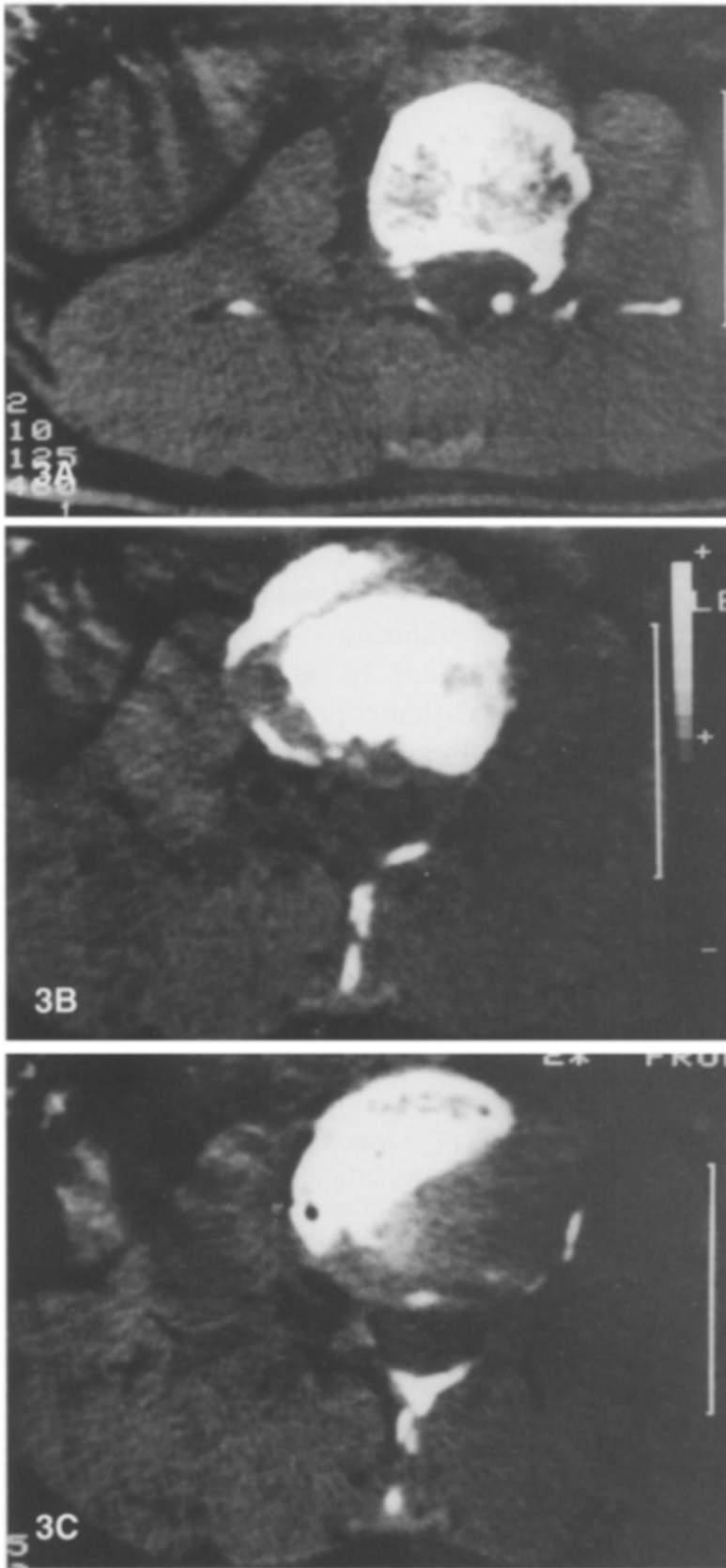


Figure 3. Sequential CT scans of the level L2 showing absence of the pedicles and the neural arch.

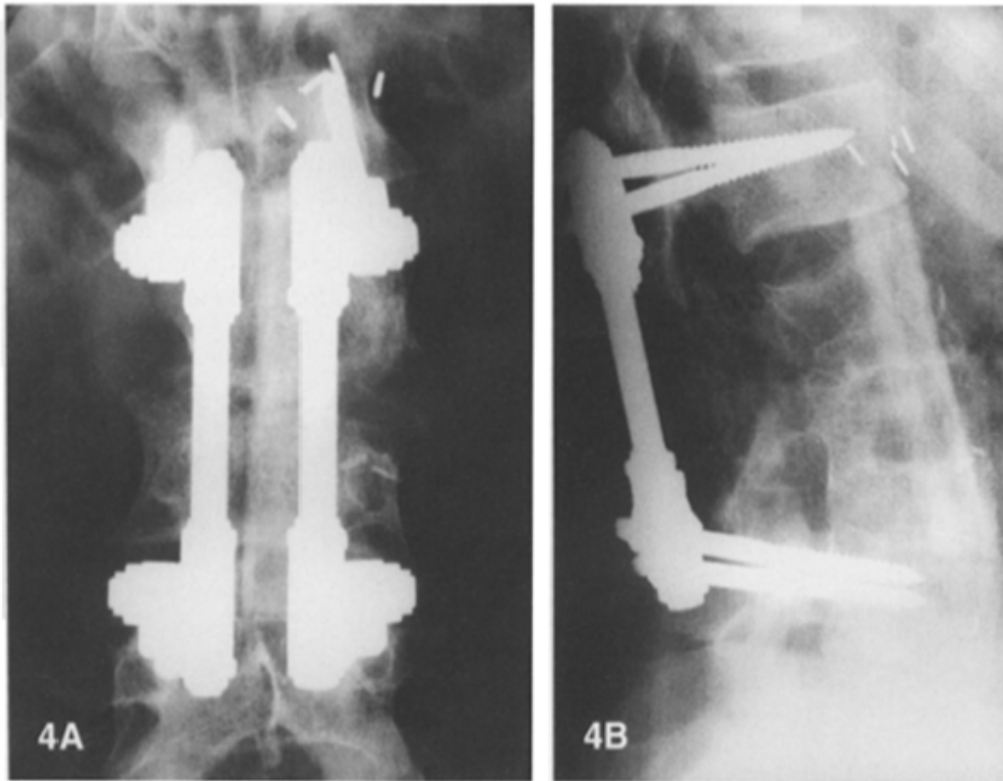


Figure 4 A. B. AP and lateral views 5 years after operation showing correction of the kyphoscoliosis, L1-L4 fusion with the anterior fibular strut graft and the Dick fixator posteriorly.