Delayed distraction in bone lengthening improved healing in lambs

Jorge Gil-Albarova, Julio de Pablos, Marco Franzeb and José Cañadell

Department of Orthopedics, University Clinic, Medical School, University of Navarra, Apdo 192, ES-31080 Pamplona, Spain.
Correspondence: Dr. Jorge Gil-Albarova, Moncasi st. 16, 2° Dcha, ES-50.006 Zaragoza, Spain. Tel +34-976 277 676

ABSTRACT

We compared delayed distraction (DD) with immediate distraction (ID) in bone-lengthening. Open femoral diaphyseal osteotomy was performed on 24 three-month-old lambs, and extemal distractor fixators were applied. In the ID group (n 12), distraction commenced on the first postoperative day; in the DD group (n 12), distraction was delayed until the tenth day alter surgery. In all the animals, the femur was lengthened by 2 cm at the rate of 1 mm/day. The animals were killed 1, 2, and 3 months postoperatively. Radiography and densitometry of the lengthened callus showed that DD, compared with ID, improved the quality of the callus with quicker, denser, and more homogeneous bone formation.

INTRODUCTION

Among the methods for bone lengthening, the concept of callotasis, introduced by De Bastiani et al. (1987), is now widespread. This is a technique for progressive lengthening by means of open osteotomy, usually diaphyseal, followed by careful surgical repair of the periosteum. After a certain period of time has elapsed, progressive bone distraction is started. Kawamura et al. (1968) questioned the importante of deferring distraction, and suggested that if osteotomy is performed percutaneously and subperiosteally with minimum dissection of the soft tissues (Kawamura et al. 1981), this step in the lengthening technique can be dispensed with. White and Kenwright (1990) used contact microradiography to demonstrate that in rabbits where distraction was deferred for 7 days, a greater volume of callus was obtained than in animals subjected to immediate distraction (ID).
We assessed the effect of delayed distraction (DD) on bone lengthening. At the same time, an attempt was made to evaluate the application and usefulness of bone densitometry as a quantitative method in the follow-up of bone regenerated in distraction, and as a source of additional information to complement conventional radiography.

MATERIAL AND METHODS

24 male lambs aged 3 months were subjected to a 2-cm elongation in the left femoral mid-diaphysis after open osteotomy and periosteal stripping. The osteotomy was performed with an oscillating saw, followed by circumferential stripping and excision of the periosteum for 15 mm proximally and distally. The fixatordistractor system used was an experimental prototype of the dynamic axial fixator (Orthofix®) designed at the University of Verona (De Bastiani et al. 1984, 1986). Placement of the device was performed in aseptic conditions, under general anesthesia induced by intravenous injection of Thiobarbital (12 mg/kg) and radiographic control. Weight bearing was allowed from the day of operation.

The 24 animals used were randomly divided into the ID group and the DD group (10 days' delay). Both groups were subdivided into 3 subgroups of 4 animals with corresponding postoperative follow-up times of 1, 2 and 3 months. Distraction at 1 mm/day was carried out over a period of 20 days, by the end of which the limb was lengthened by 2 cm. The extemal fixator was in place until the end of the experiment. Each lamb was killed with 10 mL saturated potassium chloride, delivered into the heart.

Radiographs were taken to check correct axial alignment and bone formation, in the antero-posterior standardized projection of the femur at the end of the operation, at the start of lengthening, once lengthening had been completed, and at death.

Densitometry

Digital radiographic quantification of bone mineral density was employed, using a Hologic QDRTM1000® X-Ray Bone Densitometer. The lambs were killed, both femurs collected with the soft tissues intact, and the bone mineral density measurement was performed on the regenerated femoral segment (Markel et al. 1990). Then the external fixator was removed. The right femur was used as the control. The results were expressed as bone mineral density (BMD) in g/cm^2. The ID and DD groups were compared using the Mann-Whitney U-test.

RESULTS

In one lamb in each of the ID and DD groups, we also observed images of the formation of periosteal bone in the diaphysis, in the proximity of the extremes of bone, which in our opinion could be due to an incomplete resection of the periosteum during osteotomy or to periosteal regeneration.

In the 1-month-group (Figure 1), we noted ossification mainly at the endosteum, and striated mineralization following a disposition parallel to the direction of traction. The callus was formed by two fronts of progressive ossification which met toward the center of the focus of lengthening, although the proximal extreme of the femur proved more productive. Newly-formed bone was denser, more abundant and more homogeneous in the DD group. The callus never filled the entire defect created by the distraction, the central distraction area remaining radiolucent.

In the 2-month-group (Figure 2), the two ossification fronts made contact in the central region of the distraction. This contact was greater in DD animals. The proximal extreme of the femur was seen to give rise to most of the bone produced, and this effect was more pronounced in DD. Radiographic images indicated the presence of consolidation in the animals subjected to DD.

In the 3-month-group (Figure 3), the DD animals showed more abundant bone growth and incipient corticalization. In both DD and ID, the apposition of periosteal bone was visible. Nonetheless, the ID group did not yield such obvious radiographic images of corticalization of the regenerated bone.

Densitometry

The mean BMD of the control femurs of the 24 animals was 0.93 (0.71-1.2) g/cm^2. In both groups of animals, BMD of the lengthened segment increased progressively, but this increase was always higher in the DD groups (Table 1).

DISCUSSION

Open osteotomy in the mid-diaphysis has a lower osteogenic capacity than does a percutaneous osteotomy of the metaphyseal area (Arrien 1986). Moreover, the periosteum in bone lengthening has a decisive role (De Bastiani et al. 1987, Kojimoto et al. 1988). We decided to perform the osteotomy in the mid-diaphysis, followed by circumferential stripping and excision of the periosteum to reinforce a possible difference between ID and DD.

In rabbit experiments, White and Kenwright (1990) found that the bone reconstruction obtained by ID is formed mainly at the expense of the proximal extreme of bone, while in DD the two fronts of ossification, proximal and distal, seem to make a similar contribution to reconstruction; their contact microradiography showed a greater density of vessels at the focus of segments lengthened by DD. Moreover, the vascular supply from the periosteum and the soft tissues was greater than in ID. In addition to this, they found a greater volume of callus in the group of animals which underwent DD. We found a similar level of osteogenic activity at both extremes of the bone, with the proximal extreme predominating. Like White and Kenwright (1990), we observed by simple radiographic studies that a greater volume of callus was obtained by DD.

We observed a radiotransparent zone, which was situated centrally in a transverse position flanked by the two fronts of ossification emanating from the two extremes of the bone. This area grew progressively narrower in the course of the consolidation stage, once the period of distraction had ended. The role of the periosteum in the ossification of the lengthened segment, given that the osteotomy performed in our study was accompanied by deperiostization at this point, was not evident radiographically until 2-3 months after surgery. Thus in the initial stages the ossification of the lengthened segment was primarily endosteal.

Peretti et al. (1989) suggested that repetition of densitometric studies of the lengthened segment at certain intervals would document mineralization and may even establish the time at which it became mechanically stable. Quantitative CT has been considered useful in the clinical situation, because it may correlate with the mechanical strength of new bone for optima (timing of fixator removal (Aronson et al. 1990). Our data confirm this possibility. We even observed that 2 of the animals from the DD group which were killed 2 months after surgery, and another 2 from the same group killed at 3 months, had a greater BMD in the lengthened segment than in the contralateral femur which we were using as a control. For these reasons, we consider that mineral density measurement could be used to monitor bone lengthening.

REFERENCES

1. Aronson J, Good E, Stewast C, Harrison B, Harp J. Preliminary studies of mineralisation during distraction osteogenesis. Clin Orthop 1990; 250: 43-9.
2. Arrien A. Estudio comparativo de las osteotomías a cielo abierto y percutanea en la elongación osea. Thesis, University of Navarra, Pamplona, Spain 1986.
3. De Bastiani G, Aldegheri R, Renzi Brivio L. The treatment of fractures with a dynamic axial fixator. J Bone Joint Surg (Br) 1984; 66 (4): 538-45.
4. De Bastiani G, Aldegheri R, Renzi Brivio L. Dynamic axial fixation. A rational altemative for the extemal fixation of fractures. Int Orthop 1986; 10 (2): 95-9.
5. De Bastiani G, Aldegheri R, Renzi Brivio L, Trivella G. Limb lengthening by callus distraction (callotasis). J Pediatr Orthop 1987; 7 (2): 129-34.
6. Kawamura B, Hosono S, Takahashi T, Yano T, Kobayashi Y, Shibata N, Shinoda Y. Limb lengthening by means of subcutaneous osteotomy. Experimental and clinical studies. Bone Joint Surg (Am) 1968; 50 (5): 851-78.
7. Kawamura B, Hosono S, Takahashi T. The principies and technique of limb lengthening. Int Orthop 1981; 5 (2): 69-83.
8. Kojimoto H, Yasui N, Goto T, Matsuda S, Shimomura Y. Bone lengthening in rabbits by callus distraction. The role of periosteum and endosteum. J Bone Joint Surg (Br) 1988; 70 (4): 543-9.
9. Markel M D, Wikenheiser M A, Morin R L, Lewallen D G, Chao E Y S. Quantification of bone healing. Comparison of QCT, SPA, MRI, and DEXA in dog osteotomies. Acta Orthop Scand 1990; 61 (6): 487-98.
10. Peretti G, Memeo A. Paronzini A, Marionori E C. Metodische per lo estudio dell callo osseo nell' alloungamento degli arti. G Ital Ortop Traum 1989; 15: 235-40.
11. White S H, Kenwright J. The timing of distraction of an osteotomy. J Bone Joint Surg (Br) 1990: 72 (3): 356-61.

Table 1. Median (range) bone mineral density (g/cm^2) of distraction callus		
Follow-up (mo)	**ID**	**DD**
1	0.24 (0.22-0.26)	0.43 (0.28-0.58)
2	0.27 (0.11-0.36)	0.73 (0.30-1.1)
3	0.60 (0.41-0.73)	0.94 (0.61-1.2)
$P < 0.05$, at all time intervals.		

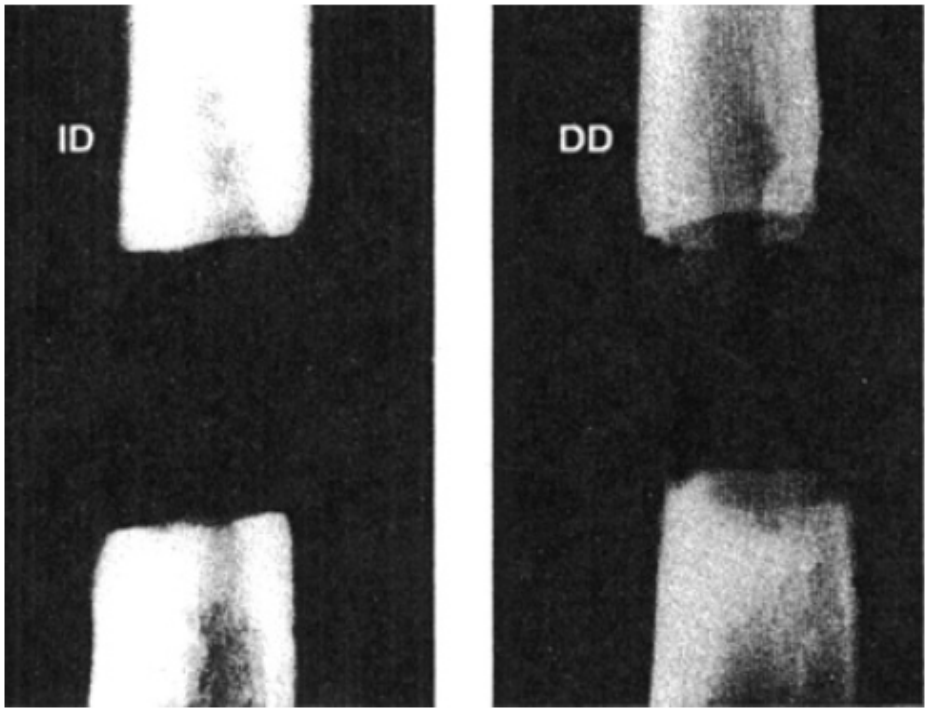

Figure 1. 1 month after surgery. Note the greater density of the newly-formed bone in DD with respect to that created in ID.

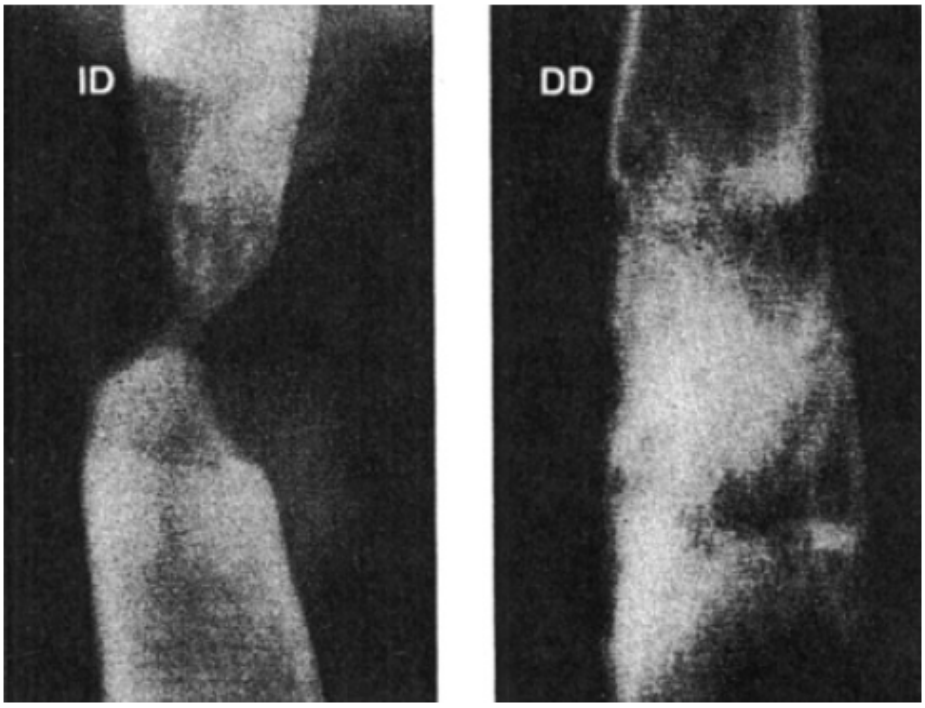

Figure 2. 2 months after surgery. The two fronts of ossification make contact, in both DD and ID. The bone healing by DD presents images of consolidation.

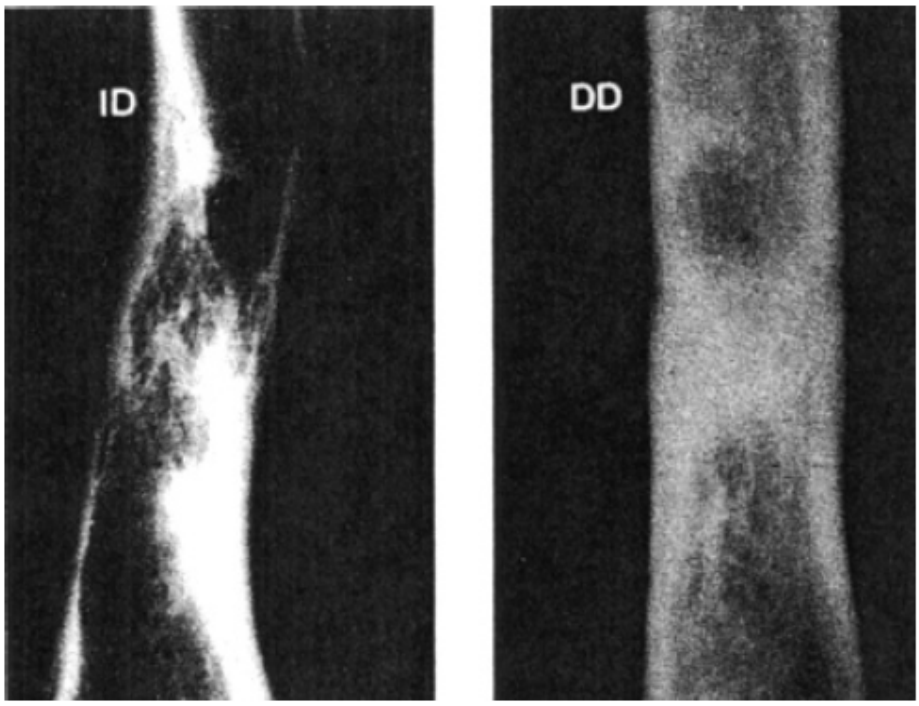

Figure 3. 3 months after surgery. Both subgroups show radiographic consolidation. The DD subgroup shows bone healing with corticalization, which is not yet present in the ID subgroup.