

Soft Tissue Behavior During Limb Lengthening: An Experimental Study in Lambs

Jorge Gil-Albarova, Margarita Melgosa, *Oscar Gil-Albarova, and José Cañadell

Departments of Orthopaedics and *Cardiovascular and Thoracic Surgery, University Clinic Medical School, University of Navarra. Pamplona, Spain.

Address correspondence and reprint requests to Dr. Gil-Albarova. Fray Luis Amigó 2. 1°C. 5006 Zaragoza. Spain.

SUMMARY

The effect of femoral elongation on skeletal muscle, nerves and vessels was studied. Three groups of five lambs were used. After the intervention, the animals were killed at 2, 3, and 4 months. A left femoral elongation of 6 cm was practiced on all of them by means of callotasis, with a distraction rate of 0.5 mm every 12 hours. The femoral elongation process was evaluated by monthly x-ray films. The nucleic acid and protein levels in the muscular tissue were quantified at the level of the elongation focus and in the control extremity. The motor conduction velocity of the sciatic nerve was measured in both posterior limbs before the intervention and immediately before the lambs were killed. The arterial blood flow of both subsequent extremities was measured at the moment of death. A histological study of quadriceps muscle, sciatic nerves, artery, and subsequent femoral vein were examined histologically at the level of the elongation focus of both extremities.

After elongation, no significant differences were observed in the muscle protein and nucleic acid levels with respect to the control extremity. No significant changes of the nerve conduction velocity were observed in any animal among the different groups. The arterial blood flow of the elongated extremity showed a progressive increase, reaching its maximum value 1 month after the distraction had terminated, with subsequent normalization. This increase of the blood flow was also observed in the control extremity, suggesting a possible systemic effect. The histological study revealed a comparative thickening of the endomysium and perimysium in the elongated muscle tissue, present at the end of the distraction and which was later normalized. No histological changes of the nerve stems undergoing distraction were observed either. During elongation, the arteries showed minimal histological changes. On the other hand, the veins showed areas of endothelial damage accompanied by thrombosis phenomena, especially at the end of the distraction period. The vascular morphology presented progressive normalization after the distraction phase.

KEY WORDS

External fixation; Limb lengthening; Soft tissues.

INTRODUCTION

Bone lengthening can be limited in its extent by the response of the soft tissues, of acute or insidious presentation, to the progressive increase of tension. Muscle contracture and loss of strength (8,27,41,46,61) have been mentioned among the effects of bone elongation on muscle tissue. Signs of muscle tissue growth have been observed, which disappear after distraction (30-32,53,57). One of the most important complications during limb lengthening is nerve injury. This injury may appear intraoperatively by direct injury of a nerve stem (40,45), by an extemporaneous elongation of the member (6,36, 43), or during the progressive distraction phase (10,46,58). In human clinical practice, fractionating of the distraction has been recommended, adapting its rhythm to the biological response of each patient, thus significantly reducing the risks of nerve injury from traction (37,46). Among the effects that bone elongation can cause on the cardiovascular system, arterial hypertension (16,46), alterations of the blood flow (BF) of the extremities (22,23,25), and structural alterations of the blood vessels (19,20,26,35,48) have been cited. In the present work we study the functional and histological response of muscle, nerves, and vessels during extremity elongation.

METHOD

Fifteen 10-week-old lambs with an average weight of 15.4 kg were used. They were divided into three groups of five animals according to the time of external fixation: 2 months (Group A), 3 months (B), and 4 months (C). A percutaneous diaphyseal osteotomy of the left femur was performed under general anesthesia. By means of a Wagner's external fixator, a femoral elongation of 6 cm was achieved, the distraction beginning on the first postoperative day at a rate of 0.5 mm every 12 hours. X-ray films of the left femur were taken in a standardized anteroposterior projection intraoperatorily and later monthly. The free movement of the animals was permitted postoperatively with full load on the extremity intervened. The right extremity served as control.

Under sedation with 1 mg of intramuscular flunitrazepam, the sciatic nerve motor conduction velocity of both posterior limbs was measured preoperatively and immediately before death using a Medelec Ms 92a apparatus. The needle electrode of proximal stimulation was implanted between the medium and deep gluteal muscles at the level of the hip joint. The needle electrodes of distal stimulation were placed at the level of the popliteal cavity. The distal electrodes were implanted in the lateral flexor muscle of the toes at the level of the most proximal section of the tibia. Under general anesthesia, immediately before death, the BF of the common femoral artery (CFA), anterior femoral artery (AFA), and anterior tibial artery (ATA) was measured in both posterior extremities. This measurement was carried out by means of gauged probes attached to a Cliniflow II FM7OIDE (Carolina Medical Electronics Inc.) apparatus before the dissection of these vessels. Under general anesthesia, immediately before death, samples were taken of the external vast muscle, sciatic nerve, posterior femoral artery (PFA), and posterior femoral vein (PFV) at the level of the elongation focus in both posterior extremities. Muscle specimens were processed for nucleic acid and protein measurement according to methods previously published in detail (7,9). The histological preparations were stained with hematoxylin-eosin and Masson's trichrome. The animals were killed with an intravenous overdose of C1K. The statistical study was carried out by means of the Mann-Whitney U test.

RESULTS

Fractures were not produced, although a mild varixation of the elongation focus was observed in the final phase (Fig. 1). No clinical manifestations of neurological deficiency of the limb intervened were observed in any of the animals. The lambs presented a stiffness of the left knee during the distraction phase, which disappeared progressively.

Nucleic acid and protein measurement

Tables 1 and 2 show the protein and nucleic acid values. No significant differences were observed in the values obtained from both extremities at the moment of death in any of the animal groups.

Nerve conduction velocity

Tables 3 and 4 show the data of the motor conduction study. No significant differences in the motor conduction velocity values were observed between both limbs preoperatively or immediately before death. No significant differences were observed between the latency values either.

Blood flow

Table 5 shows the results of the BF measurement. All the animals showed a greater BF in the elongated extremity at the three levels of measurement with respect to the control extremity. The differences were significant at the three levels: CFA ($p < 0.005$), AFA ($p < 0.05$), and ATA ($p < 0.001$). The BF reached its maximum values in Group B, killed a month after the distraction terminated. There were no significant differences between the values of Groups A and C.

Histological changes

The muscle tissue of the elongated extremities (Fig. 2) showed a thickening of the endomysium and perimysium at the end of the distraction (Group A), which was progressively normalized in the animals of Groups B and C. Sciatic nerve of the elongated limbs presented no histological differences with respect to that of the control limbs (Fig. 3). No alterations of the epineural and perineural connective tissue were seen. In one Group B animal, the presence of an inflammatory infiltration was observed surrounding the intraneural vessels in the sciatic nerve undergoing distraction (Fig. 4). No histological differences were observed between the wall of the elongated PFA and the control in the three groups. Occasionally, erythrocyte aggregates were observed in the proximity of the arterial endothelium both in the elongated arteries as well as in the controls of Group A (Fig. 5). These findings were not observed in Groups B and C. The elongated PFV showed areas of endothelial loss accompanied by thrombosis phenomena in Group A (Fig. 6). Once the distraction terminated, normal morphology recovered progressively; small areas of endothelial damage were observed in some animals of Group C.

DISCUSSION

Because of the progressive tension of the soft tissues, the lambs presented a stiffness of the left knee during the distraction phase, which disappeared progressively. This fact is frequently observed in humans as a response to the contracture of the strongest muscle group of the elongated bone segment (11,46).

Nucleic acid and muscle protein measurement

No significant differences were observed between the nucleic acid and protein values of the elongated muscle with respect to those of the control muscle. This finding suggests the absence of hyperplasia or muscular hypertrophy at the level of the central section of the elongation focus. This observation contrasts with those of Ilizarov (19,20), who considered that the muscular tissue subjected to progressive distraction grows by means of fusion in myotubes from myoblasts proliferating throughout the muscle if the length increase does not exceed 20%. To this respect, Yasui et al. (59) stated that they cannot specify how this process, also observed by Schumacher et al. (53) in rabbits, is carried out. The fact that in our animals the final length increase reaches 50% would justify these differences.

Schultz (52) considered that, during the growth, the process of myogenesis is carried out from a subpopulation of myoblasts, which continues throughout the lifetime. Their proliferation produces a progressive increase of the nucleic acid contents of the myofibrils, that stabilizes on reaching maturity. This method can be reactivated, for reparative purposes, in response to a muscular injury, although its intensity is inversely proportional to the age and muscular weight of the individual. Our results suggest that this phenomenon would not be carried out at the level of the elongation focus because of no increase in the nucleic acid or muscle protein contents at said level.

For Kochutina (30-32) this phenomenon takes place at the level of the tenomuscular joints when an elongation by means of double corticotomy is performed. Griffin et al. (12) considered that muscle growth is carried out in the tenomuscular joints by means of the addition of new sarcomeres at this level and not all along the growing myofibrils. Ilizarov (20,21) established that, during extremity elongation, the proliferative, metabolic, and biosynthetic changes in the cellular activity of the elongated tissues are similar to embryonic and fetal histogenesis as well as to postnatal extremity growth. Although other authors (2,17,49,57) claimed that progressive distraction provokes skeletal muscle hypertrophy, our results do not support this fact at the level of the osteotomy without denying the fact that this phenomenon is at the level of the tenomuscular joints.

Nerve function study

The absence of clinical and functional manifestations in our study contrasts with those reported by other authors. Thus, Wall et al. (62) together with Kwan et al. (34) reported in vivo an impairment of the function of the tibial nerve in rabbits after subjecting them to different percentages of maintained tension. The time between the application of the tension and the appearance of the functional impairment was in direct relation to the magnitude of the applied tension as well as the capacity of functional recuperation. Similar findings were observed by Lundborg and Rydevik (38,51) in their in vitro

models as well as by Yong Lee et al. (66) using evoked potentials in rabbits. Brown et al. (4), indicated the wide variety of tension limits in the biomechanical studies of the peripheral nerves, most of which use in vitro models.

Mizumoto et al. (44) reported differences in the latency values if a motorized distraction is used with respect to a distraction in two sequences, which did not exceed 1 mm/day, observing less damage to the nerve function with the motorized distraction. Simpson and Kenwright (55) reported an impairment of the nerve function after carrying out a progressive distraction in rabbits, if a tension of 2% a day is exceeded. Kenwright (29) calculated the magnitude of the tension necessary to cause functional damage to be 15%. Battiston et al. (3) did not find functional nerve damage in rats if the distraction velocity did not exceed 1 mm/day, coinciding with that observed in our results. However, Strong et al. (58) observed, in dogs undergoing femoral elongation, normality in the nerve conduction study with electromyographic signs of denervation, locating the nerve damage at a proximal level to that of the elongation.

In human clinical studies, Galardi et al. (10), together with Davis et al. (8), observed a reduction of the motor conduction velocity as well as a partial motor denervation without clinical effects in patients undergoing tibial elongation following Ilizarov's technique. Cañadell et al. (5) also observed electromyographic alterations in 85% of patients undergoing limb elongation, although without clinic repercussion.

Young et al. (67), as well as Cañadell et al. (5), observed a fundamentally neuropathic pattern in their patients. For Young et al. (67), the cause was the rise of progressive tension associated with a rise of intracompartmental pressure, capable of altering the intraneural blood flow without a real compartmental syndrome being established. This hypothesis, already suggested by Galardi et al. (10) and Davis et al. (8), is supported by the observations of Mizumoto et al. (44), who reported a gradual decrease of the intraneural blood flow in relation to progressive distraction in rabbits. In this way, the pathogenesis of functional nerve damage during limb elongation would be explained by the association of mechanical damage with the ischemia provoked by a subacute compartmental syndrome. On the other hand, Brown (4) and Makarov (40) and their colleagues considered that the presence of scar tissue, which changes the elastic behavior of the nerve stems undergoing distraction, may facilitate the appearance of functional damage in the same.

Blood flow measurement

Our results showed a mean BF increase of 151% in the elongated extremity. This increment represents an intermediate value between the findings of Lavini et al. (35) and Schwartsman (54) in patients undergoing extremity elongation. Their results range widely, from a 43 to 330% increase of the BF, measured by different methods. Ilizarov (19-21) suggested the possibility of improving the clinical condition of some patients affected by occlusive vascular diseases by means of techniques of bone elongation.

The maximum values of BF were observed in the killed animals a month after the distraction ended (Group B); the values reached in Groups A and C were similar. This fact suggests that progressive distraction may have a transient and deferred effect in BF increase. Our findings agree with those observed in rats by Grundnes and Reikerås (13,14). Using labeled microspheres, they reported that, between 4 and 8 weeks after

performing an osteotomy, the blood flow of the bone and of the peripheral musculature increased significantly, later recovering its normal values. Kelly et al. (28), along with Grundnes and Reikerås (13,14), suggested that this increase of BF indicates a metabolic requirement of the bone repair process, although this response may be conditioned by other factors. Similar observations have been reported by Aalto (1) with rabbits and Zdeblick et al. (68) with dogs. Wallace et al. (63), in their study of lambs, observed that the BF presents a similar behavior at the level of a diaphyseal osteotomy stabilized with a dynamic external fixator if the adjacent soft tissues were preserved. In contrast to Wallace's study, our system of external fixation was rigid. Kofoed et al. (33) explained the increment of BF as a response to the tissular hypoxia provoked by the osteotomy followed by an angiogenesis stimulus.

The BF increase was also observed in the control extremities, perhaps as an expression of a systemic effect that the distraction would cause on the peripheral BF. Although the BF increase is able to stimulate bone growth (15,42,47,64), the final length difference of the femurs of our animals did not exceed 6 cm. An explanation of this fact is that said stimulus might have been the same on both extremities; therefore, the final difference of femoral length did not exceed that provoked by elongation.

Histological changes

Muscle

The elongated muscle showed a comparative thickening of the perimysium in the animals of Group A, which disappeared progressively in Groups B and C. This finding coincides with the observations of Kochutina et al. (30-32) in dogs and those of Yong Lee et al. (60) and Simpson et al. (56) in rabbits. According to Yong Lee et al. (60), these findings after a 20% length increase suggests irreversible muscular damage. Povkov et al. (49) asserted that these histological changes disappear progressively after the distraction ends and the system of external fixation is removed. For Simpson et al. (56), the histological changes of the muscle tissue subjected to distraction are minimal if a distraction rate of 1 mm/day is not exceeded. Kochutina et al. (30-32) reported dystrophic and degenerative changes accompanied by regenerative phenomena when an elongation by means of double osteotomy is performed and at a rate of 2 mm/ day. On the other hand, Pouliquen et al. (50) in rabbits and Peretti et al. (48) in calves did not observe morphological changes in muscle subjected to different distraction rates.

Matano et al. (41) reported differences between the percentage of muscle and bone elongation. In their observations, this percentage is higher in the muscle than in the bone. They, therefore, suggest the necessity of considering this fact in bone extremity elongations to avoid excessive tension on muscle tissue. The histological changes observed by different authors might be related to the transitory functional loss observed by Mafulli et al. (39) and Käljumäe et al. (27) in patients subjected to bone elongation, who, according to Holm et al. (18), tend to recover completely.

Nerve

Endoneural and perineural integrity after subjecting a nerve to tension has been considered a positive factor with respect to the maintenance of the nerve function (34,51,62). This observation would support the absence of functional disorders in our animals in relation to the conservation of the endoneural and perineural structures

observed in the histological study. Our results contrast with those of Pouliquen et al. (50), who observed nerve fiber rupture and vacuolar degeneration images in rabbits undergoing femoral elongation at a distraction rhythm greater than 1 mm/day as opposed to our experimental model. Battiston et al. (3) observed proliferation of connective tissue and of Schwann's cells of the sciatic nerve of rats undergoing progressive distraction, with an absence of functional impairment if the distraction rate did not exceed 1 mm/day.

For their part, both Peretti et al. (48) and Ippolito et al. (26) observed, in calves undergoing metacarpal elongation, that in the first stages of the distraction injuries were already appearing in the myelin sheath in the fibers of greater diameter. These injuries were associated with images of axonal degeneration when the elongation obtained was greater. According to their observations, were the myelin fibers of smaller diameter together with the amyelin fibers which best support progressive distraction (26,48). Similar findings were reported by Kochutina et al. (32) in dogs undergoing femoral elongation: the degenerative and regenerative phenomena of the nerve fibers coexisting during the distraction phase, with prevalence of the regenerative at the end of this phase.

The intraneural vessels of our lambs did not present any alterations. This observation contrasts with the physiopathology of nerve injury caused by traction suggested by Lundborg et al. (38) and Rydevik et al. (51), considering that progressive tension would lead to an intraneural vascular occlusion with secondary ischemia. Other authors have tried to explain functional nerve impairment by the mechanical deformation caused by tension (34,62) and by a possible disorder of calcium metabolism at the level of the nerve ends (65).

Vessels

Ilizarov (19,20) established that, during the extremity elongation, the proliferative, metabolic, and biosynthetic changes in the cellular activity of the elongated tissues are similar to embryonic and fetal histogenesis as well as to postnatal extremity growth. Just as Pouliquen et al. (50) observed in rabbits, we found minimal tissue changes in the vessels present at the end of the distraction stage after the initial femoral length had increased by 50%, and which later disappeared. However, Peretti et al. (48) and Ippolito et al. (26) observed atrophy of the arterial middle tunic in calves with duplication of the internal elastic membrane, vacuolization of the muscular fibers, and partial loss of the contractile proteins when the elongation exceeded 20%. They also observed, as did Ilizarov (19-21), transitory thinning of the venous wall, with the presence of degenerative and regenerative phenomena. In the same way as in our observations, such alterations were normalized 2 months after the distraction stage ended. Our results, together with those of these authors, suggest that arterial vessels are more resistant than venous vessels to progressive distraction.

The observation of thrombosis phenomena was previously reported by Ilizarov et al. (19,22-25) in dogs as a systemic effect. Ilizarov attributed this observation to an alteration of the physiological balance of coagulation provoked by too rapid a distraction or by the instability of the system of external fixation. Our observations support this possibility because phenomena of thrombosis could be observed in the control vessels. The endothelial damage described by Ippolito et al. (26) and Peretti et al. (48) and observed in our animals 2 months after the distraction is another explanation of this thrombosis phenomena. Pouliquen et al. (50) found in rabbits that a

more rapid distraction provokes greater venous endothelial damage. However, the distraction rate in our animals did not exceed 1 mm daily in two steps.

These histological findings may partly explain certain clinical observations during bone elongation such as the edema of the member, which has been attributed to venous deficiency or lymphatic alterations (26,46).

REFERENCES

1. Aalto K. Skeletal blood flow in the rabbit measured with radioactive microspheres. *Acta Orthop Scand* 1980;51:704.
2. Ashmore CR. Stretch-induced growth in chicken wing muscles: effects on hereditary muscular dystrophy. *Am J Physiol* 1982;242: 178-83.
3. Battiston B, Buffoli P, Vigasio A, et al. Comportamento dei nervi sottoposti ad allungamento. *G Ital Ortop Traum* 1992;18:81-8.
4. Brown R, Pedowitz R, Rydevik B, et al. Effects of acute graded strain on efferent conduction properties in the rabbit tibial nerve. *Clin Orthop* 1993;296:288-94.
5. Cañadell J, Pastor MA, Casado M, et al. Quantitative EMG studies during bone lengthening. *J Bone Joint Surg Br* 1993;75(suppl II): 157.
6. Cauchoix J, Morel G, Rey JC, et al. L'allongement extemporané du fémur. Bilan des cent premiers patients opérés. *Rey Chir Orthop* 1972;58:753-74.
7. Ceriotti G. Determination of nucleic acids in animal tissues. *J Biol Chem* 1955;214:59-70.
8. Davis RJ, Bell DE, Crowley N, Redmond MD. Electromyographic changes following limb lengthening: a prospective study. *J Pediatr Orthop* 1992;12:821.
9. Eisemann JH, Hammond AC, Rumsey TH. Tissue protein synthesis and nucleic acid concentration in steacus treated with somatotrophin. *Br J Nutr* 1989;62:657-71.
10. Galardi G, Comi G, Lozza L, et al. Peripheral nerve damage during limb lengthening. *J Bone Joint Surg Br* 1990;72:121-4.
11. Green SA. Postoperative management during limb lengthening. *Orthop Clin North Am* 1991;22:723-34.
12. Griffin GE, Williams PE, Goldspink G. Region of longitudinal growth in striated muscle fibers. *Nature New Biol* 1971;232:28-9.
13. Grundnes O, Reikerås O. Effect of physical activity on muscle and bone blood flow after fracture: exercise and tenotomy studied in rats. *Acta Orthop Scand* 1991;62:67-9.
14. Grundnes O, Reikerås O. Blood flow and mechanical properties of healing bone. Femoral osteotomies studied in rats. *Acta Orthop Scand* 1992;63:487-91.
15. Harris RI, McDonald JL. The effect of lumbar sympathectomy upon the growth of legs paralysed by anterior poliomyelitis. *J Bone Joint Surg Am* 1981;63:35-53.
16. Helal A, Guidera KJ, Campos A, et al. Hypertension following orthopaedic surgery in children. *J Pediatr Orthop* 1993;13:773-6.
17. Holly RG, Barnett JG, Ashmore CR, et al. Stretch-induced growth in chicken wing muscles: a new model of stretch hipertrophy. *Am J Phvsiol* 1980;238:62-71.

18. Holm I, Steen H, Ludvigsen P, Bjerkreim I. Unchanged muscle function after bilateral femoral lengthening: a prospective study of 9 patients with a 2-years follow-up. *Acta Orthop Scand* 1995;66: 258-60.
19. Ilizarov GA. The tension-stress effect on the genesis and growth of tissues: Pan I. *Clin Orthop* 1989;238:249-81.
20. Ilizarov GA. The tension-stress effect on the genesis and growth of tissues: Pan II. *Clin Orthop* 1989;239:263-85.
21. Ilizarov GA. Clinical application of the tension-stress effect for limb lengthening. *Clin Orthop* 1990;250:8-26.
22. Ilizarov GA, Gordievskiyh NI. Distraction rate influence upon certain hemodynamic values of musculus gastrocnemius of operated limb. In: *Proceedings of the Anniversary Scientific Conference with International Participation*. Kurgan: 1991:130-1.
23. Ilizarov GA, Kuznetsova AB, Peschanskii VS, et al. Blood vessels in different system of limb traction: experimental study. *Arkh Anal Gistol Embriol* 1984;86:49-55.
24. Ilizarov GA, Sbrodova LI, Larionov AA, Naumov AD. Coagulation and fibrinolytic blood and muscular potential in distraction osteosynthesis in experiment. In: *Proceedings of the Anniversary Scientific Conference with International Participation*. Kurgan: 1991:132-3.
25. Ilizarov GA, Shurov UA, Dolganova TI, et al. Limb blood supply in stimulating effect of mechanical factors on regeneration and growth. In: *Proceedings of the Anniversary Scientific Conference with International Participation*. Kurgan: 1991:131-2.
26. Ippolito E, Peretti G, Bellocchi M, et al. Histology and ultrastructure of arteries, veins, and peripheral nerves during limb lengthening. *Clin Orthop* 1994;308:54-62.
27. Käljumäe U, Märtson A, Haviho T, Hänninen O. The effect of lengthening of the femur on the extensors of the knee. *J Bone Joint Surg Am* 1995;77:247-50.
28. Kelly PJ, Montgomery RJ, Bronk JT. Reaction of the circulatory system to injury and regeneration. *Clin Orthop* 1990;254:275-88.
29. Kenwright J. Mechanical and biological responses of tissues to leg lengthening. *Abstracts of the ISRF Symposium on Callus Distraction*. Ottrott-Le-Haut: 1992;22-3.
30. Kochutina LN. Regeneration myogenesis of shank muscles during experimental lengthening. *Izvest Akad Nauk SSSR Ser Biol* 1990; 4:565-70.
31. Kochutina LN, Klishov AA. Peculiarities of myohistogenesis under conditions of mono and bilocal distractive osteosynthesis in experiment. *Arkh Anat Gistol Embriol* 1989;97:44-52.
32. Kochutina LN, Kudriavtseva IP, Chumasov EI, Svetikova KM. Changes in neural conductors and their organs in the muscles and skin after major procedures of one-stage lengthening of the extremity by the GA Ilizarov method. *Arkh Anat Gistol Embriol* 1990;98:24-31.
33. Kofoed H, Sjøntoft E, Siemssen SO, Olesen HP. Bone marrow circulation after osteotomy. Blood flow, pO₂, pCO₂ and pressure studied in dogs. *Acta Orthop Scand* 1985;56:400-3.
34. Kwan MK, Wall EJ, Massie J, Garfin SR. Strain, stress and stretch of peripheral nerve. Rabbit experiments in vitro and in vivo. *Acta Orthop Scand* 1992;63:267-72.

35. Lavini F, Renzi-Brivio L, de Bastiani G. Psychologic, vascular and physiologic aspects of lower limb lengthening in achondroplastics. *Clin Orthop* 1990;250:138-42.
36. Le Coeur P. Egalisation des membres inférieures par allongement avec fixation immédiate. *Rey Chir Orthop* 1963;49:217-27.
37. Leong JCY, Ma RYP, Clark JA, et al. Viscoelastic behaviour of tissue in leg lengthening by distraction. *Clin Orthop* 1979;139: 102-9.
38. Lundborg G, Rydevik B. Effects of stretching the tibial nerve of the rabbit: a preliminary study of the intraneural circulation and the barrier function of the perineurium. *J Bone Joint Surg Br* 1973: 55:390-401.
39. Mafulli N, Biol MI, Fixsen JA. Muscular strength after callotasis limb lengthening. *J Pediatr Orthop* 1995;15:212-6.
40. Makarov M, Delgado M, Samchukov M, et al. Somatosensory evoked potential evaluation of acute nerve injury associated with external fixation procedures. *Clin Orthop* 1994;308:254-63.
41. Matano T, Tamai K, Kurokawa T. Adaptation of skeletal muscle in limb lengthening: a light diffraction study on the sarcomere length in situ. *J Orthop Res* 1994;12:193-6.
42. Means JM, Vesely DG, Kennedy H. Effect of surgically induced arteriovenous fistula on leg length inequality. *Clin Orthop* 1963; 30:152-61.
43. Merle d'Aubigné R, Vaillant JM. A propos du traitement des inégalités de longueur des membres inférieures (Technique d'egalisation du fémur en un temps). *Rey Chir Orthop* 1965;51: 189-95.
44. Mizumoto Y, Mizuta H, Nakamura E, Takagi K. Tibial nerve function during tibial lengthening: Measurement of nerve conduction and blood flow in rabbits. *Acta Orthop Scand* 1995;66:275-77.
45. Paley D. Current techniques of limb lengthening. *J Pediatr Orthop* 1988;8:73-92.
46. Paley D. Problems, obstacles and complications of limb lengthening by the Ilizarov technique. *Clin Orthop* 1990;250:81-104.
47. Paterson D. Leg-lengthening procedures: a historical review. *Clin Orthop* 1990;250:27-33.
48. Peretti G, Ippolito E. Il comportamento dell'osso, della cartilagine articolare e della parte molli durante l'allungamento degli arti. *G Ital Ortop Traum* 1990;16(suppl):87-104.
49. Popkov AV, Kuznetsova LS, Djachkova Gv, Muradisinov SO. Biochemical and anatomical changes of muscles at lengthening of low extremities by Ilizarov. *Ortop Traumatol Protez* 1991;4:31-5.
50. Pouliquen JC, Chaboche P, Pennecot GF, Bergue A. Etude expérimentale du retentissement sur le cartilage de croissance et les parties molles de l'allongement progressif du fémur chez le lapin en période de croissance. *Chir Pediatr* 1980;21:363-7.
51. Rydevik BL, Kwan MK, Myers RR, et al. An in vitro mechanical and histological study of acute stretching on rabbit tibial nerve. *J Orthop Res* 1990;8:694-701.
52. Schultz E. Satellite cell behaviour during skeletal muscle growth and regeneration. *Med Sci Sports Exerc* 1989;21(suppl 5):181-5.
53. Schumacher B, Keller J, Hvid I. Distraction effects on muscle: leg lengthening studied in rabbits. *Acta Orthop Scand* 1994;65:647-50.
54. Schwartzman V, Schwartzman R. Corticotomy. *Clin Orthop* 1992; 280:37-47.

55. Simpson AHRW, Kenwright J. The response of nerve to different rates of distraction. *J Bone Joint Surg Br* 1992;74(suppl III):326.
56. Simpson AHRW, Williams PE, Kyberd P, et al. The response of muscle to leg lengthening. *J Bone Joint Surg Br* 1995;77:630-6.
57. Sproul JT, Price CT. Recent advances in limb lengthening: Part II. Biological advances. *Orthop Res*, 1992;21:425-30.
58. Strong M, Hruska J, Czmyy J, et al. Nerve palsy during femoral lengthening: MRI, electrical, and histological findings in the central and peripheral nervous systems. A canine model. *J Pediatr Orthop* 1994;14:347-51.
59. Yasui N, Kojimoto H, Shimizu H, Shimomura Y. The effect of distraction upon bone, muscle and periosteum. *Orthop Clin North Am* 1991;22:563-7.
60. Yong Lee D, Ho Choi I, Youb Chung C, et al. Effect of tibial lengthening on the gastrocnemius muscle: a histopathologic and morphometric study in rabbits. *Acta Orthop Scand* 1993;64:68892.
61. Young NL, Davis JR, Bell DF, Redmond DM. Electromyographic and nerve conduction changes after tibia] lengthening by the Ilizarov method. *J Pediatr Orthop* 1993;13:473-7.
62. Wall EJ, Massie JB, Kwan MK, et al. Experimental stretch neuropathy: changes in nerve conduction under tension. *J Bone Joint Surg Br* 1992;74:126-9.
63. Wallace AL, Draper ERC, Strachan RK, et al. The effect of devascularisation upon early bone healing in dynamic external fixation. *J Bone Joint Surg Br* 1991;73:819-25.
64. Weinman DT, Kelly PJ, Owen CA. Blood flow in bones dista] to a femoral arteriovenous fistula in dogs. *J Bone Joint Surg Am* 1964;46:1672-82.
65. Yamashita T, Oota I. Changes in post-tetanic potentiation of neuromuscular transmission in chronically stretched muscle. *Comp Biochem Physiol A* 1987;87:791-6.
66. Yong Lee D, Ryoon Han T, Ho Choi I, et al. Changes in somatosensory-evoked potentials in limb lengthening: an experimental study on rabbits' tibiae. *Clin Orthop* 1992;285:273-9.
67. Young NL, Davis JR, Bell DF, Redmond DM. Electromyographic and nerve conduction changes after tibial lengthening by the Ilizarov method. *J Pediatr Orthop* 1993;13:473-7.
68. Zdeblick TA, Shaffer JW, Field GA. The healing of canine vascularized segmental tibia] osteotomies: the effect of retained endosteal circulation. *Clin Orthop* 1988;236:296-302.

Animal	Control	Lengthened
A1	109.16	70.46
A2	86.85	76.78
A3	87.89	100.00
A4	85.14	85.08
A5	117.81	117.07
B1	101.25	118.26
B2	89.04	77.39
B3	91.20	80.90
B4	103.00	94.20
B5	91.50	87.10
C1	58.10	59.50
C2	106.19	76.04
C3	90.20	81.07
C4	87.80	98.92
C5	99.30	106.40

Animal	DNA		RNA	
	Control	Lengthened	Control	Lengthened
A1	1.85	2.02	2.23	1.69
A2	1.22	0.04	2.13	1.16
A3	1.01	0.78	3.00	3.80
A4	0.65	0.38	3.70	3.00
A5	1.80	0.38	1.60	2.09
B1	3.42	1.70	1.92	1.41
B2	1.59	1.92	1.28	1.23
B3	2.50	2.00	1.91	1.31
B4	1.33	1.37	1.71	0.98
B5	2.06	1.76	1.52	2.11
C1	1.50	1.78	1.44	2.22
C2	1.05	1.82	1.72	2.26
C3	1.57	1.75	2.01	2.10
C4	1.80	1.95	1.53	1.98
C5	1.61	1.70	1.60	1.09
DNA, deoxyribonucleic acid; RNA, ribonucleic acid.				

Table 3. Preoperative nerve conduction study

	Unoperated extremity						Operated extremity					
Lambs	TI	T2	Δ	D	A	V	TI	T2	Δ	D	A	V
A1	3.4	1.8	1.6	150	1	93.00	3.2	2.0	1.2	120	2	100.00
A2	6.6	5.0	1.6	150	3	93.00	3.0	1.6	1.4	150	3	107.00
A3	3.4	1.6	1.8	150	2	83.00	3.0	1.4	1.6	150	1	93.00
A4	5.8	3.6	2.2	180	3	81.00	5.4	3.2	2.2	180	3	81.00
A5	3.2	5.2	2.0	180	2	90.00	3.0	5.0	2.0	180	1	90.00
B1	2.4	4.0	1.6	180	2	112.50	2.4	4.0	1.6	180	1	112.50
B2	4.0	6.4	2.4	180	1	75.00	0.8	3.2	2.4	180	2	75.00
B3	5.7	3.5	2.2	180	3	81.00	5.5	3.3	2.2	180	3	81.00
B4	2.4	0.8	1.6	150	1	93.00	3.6	2.6	1.0	120	3	120.00
B5	2.4	4.0	1.6	160	3	100.00	2.4	4.0	1.6	160	1	100.00
C1	3.5	2.1	1.4	120	3	85.70	6.9	5.1	1.8	160	3	88.80
C2	6.4	4.8	1.6	150	1	93.00	3.2	1.8	1.4	150	2	107.00
C3	1.6	4.0	2.4	190	1	79.16	2.4	4.8	2.4	190	2	79.16
C4	2.4	4.8	2.4	170	3	70.80	1.6	4	2.4	180	1	75.00
C5	5.8	4.2	1.6	150	2	93.00	5.8	3.9	1.9	150	3	84.00

Table 4. Postoperative nerve conduction study

	Unoperated extremity						Operated extremity					
Lambs	TI	T2	Δ	D	A	V	TI	T2	Δ	D	A	V
A1	0.9	2.7	1.8	180	2	100.00	2.2	4.2	2.0	210	1	105.00
A2	2.0	4.2	2.2	210	1	95.45	2.4	4.6	2.2	200	3	90.90
A3	1.8	3.2	1.4	150	3	107.14	2.0	4.4	2.4	210	2	87.50
A4	5.4	3.4	2.0	200	1	100.00	3.4	6.0	2.6	210	2	81.00
A5	2.0	3.7	1.7	180	3	105.00	2.6	4.6	2.0	200	1	100.00
B1	4.4	2.7	1.7	150	1	88.23	6.1	4.2	1.9	165	2	86.84
B2	1.7	4.1	2.4	190	3	79.16	2.3	4.7	2.4	190	1	79.16
B3	3.6	2.2	1.4	120	1	85.70	6.8	5.0	1.8	160	2	88.80
B4	6.6	5.0	1.6	150	3	93.00	3.4	2.0	1.4	150	1	107.00
B5	0.9	2.7	1.8	180	3	100.00	3.2	2.0	1.2	120	2	100.00
C1	4.3	2.6	1.7	150	1	85.23	6.0	4.1	1.9	165	1	88.84
C2	2.1	4.3	2.3	210	1	95.45	2.4	4.4	2.0	210	1	105.00
C3	5.8	3.6	2.2	180	3	81.00	7.6	5.6	2.0	150	2	75.00
C4	3.4	5.4	2.0	150	1	75.00	2.3	4.7	2.4	180	3	75.00
C5	7.6	5.6	2.0	150	2	75.00	8.8	6.4	2.4	200	1	83.30

Table 5. Blood flow measurements (mL/min)

Animal	CFA		AFA		ATA	
	Control	Lengthened	Control	Lengthened	Control	Lengthened
A1	59	79	42	54	12	26
A2	80	150	67	100	19	39
A3	130	140	65	75	14	38
A4	40	60	29	42	11	25
A5	65	80	55	60	19	29
B1	100	125	75	86	23	34
B2	100	120	71	83	21	35
B3	80	120	65	90	24	34
B4	72	105	53	68	18	31
B5	65	92	55	85	21	36
C1	95	120	62	81	15	33
C2	59	84	47	53	13	31
C3	65	90	50	59	14	27
C4	73	98	64	70	18	32
C5	60	110	50	85	16	35
CFA, common femoral artery; AFA, anterior femoral artery; ATA, anterior tibial artery.						

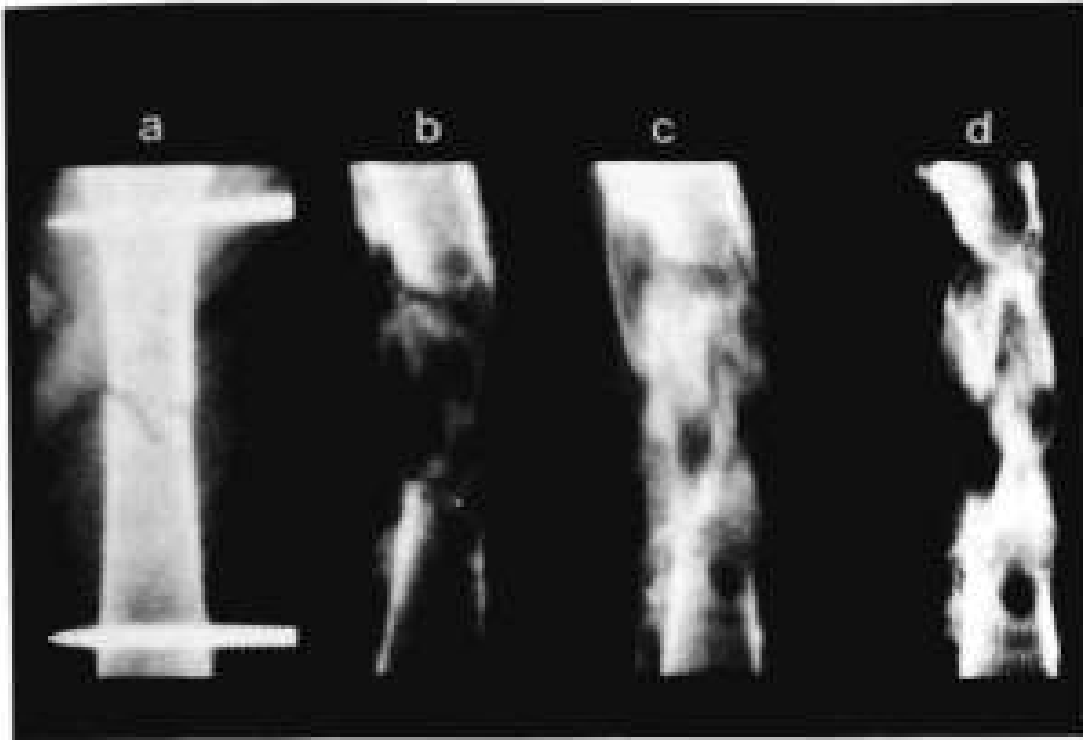


Figure 1. Radiographic image of lengthening callus: (a) immediately postoperatively; (b) 1 month postoperatively; (c) end of distraction period; (d) 3 months postoperatively.

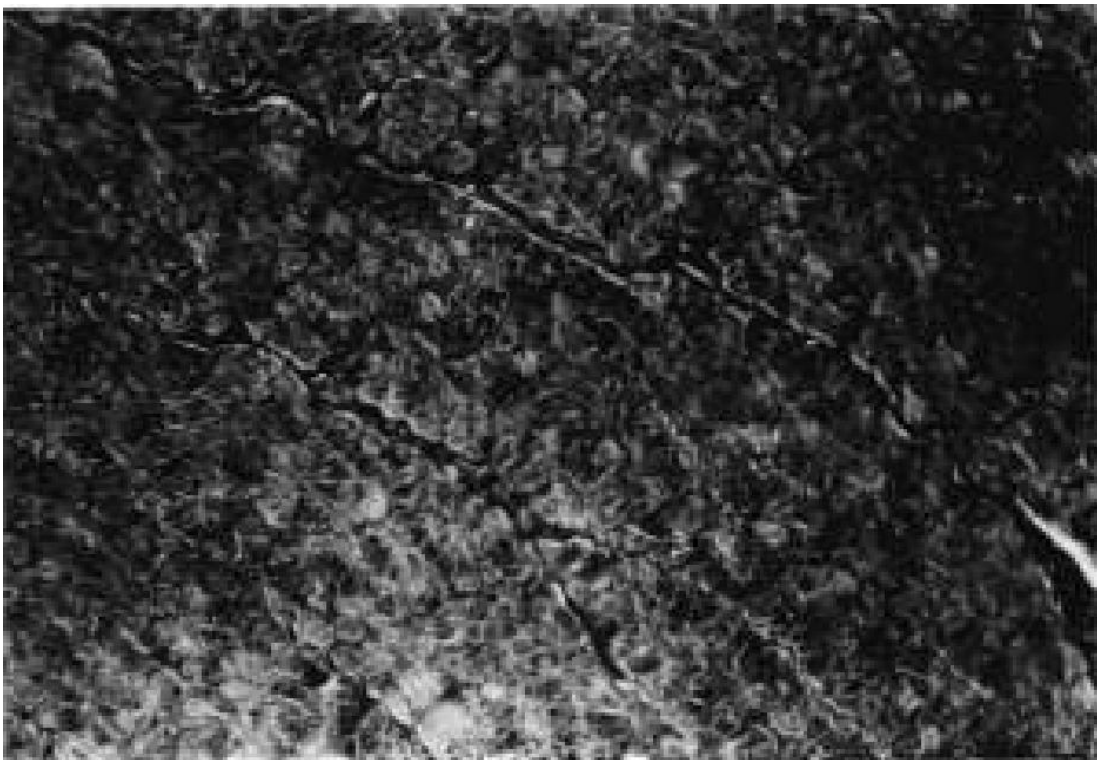


Figure 2. Lengthened muscle at end of distraction. (Masson's trichrome x300.)

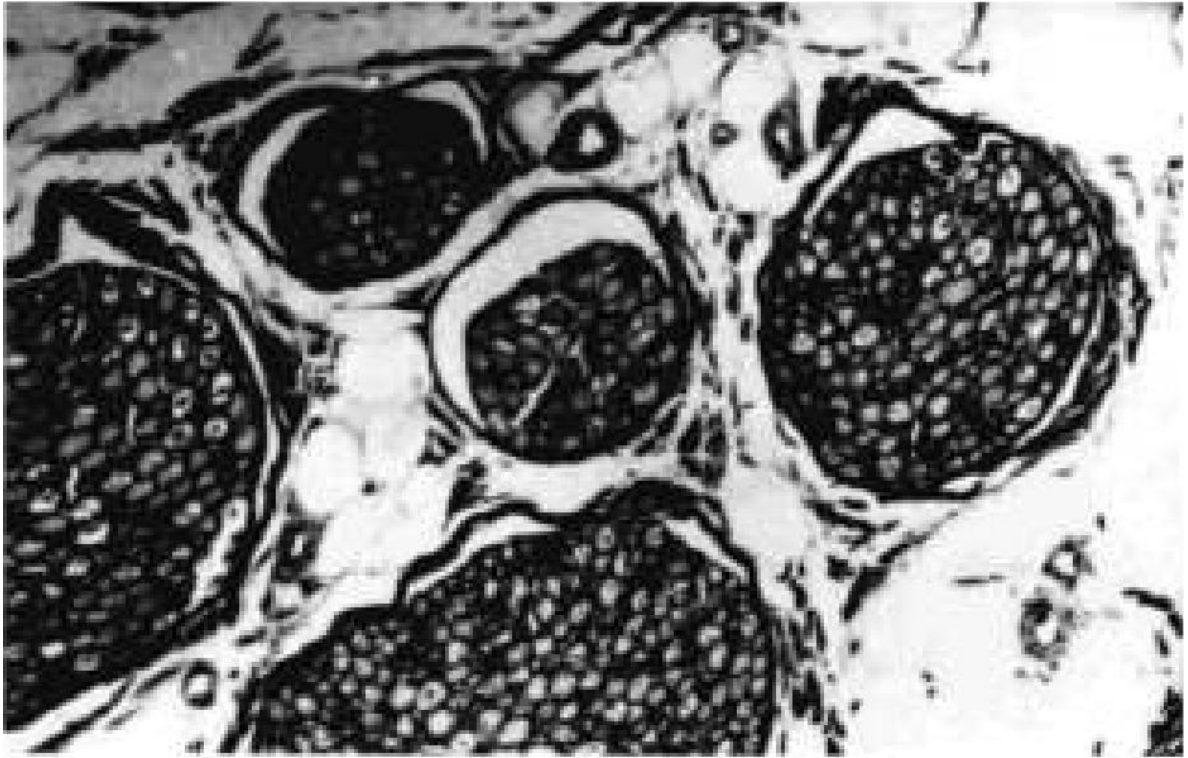


Figure 3. Lengthened nerve 2 months after distraction. (Masson's trichrome x300.)

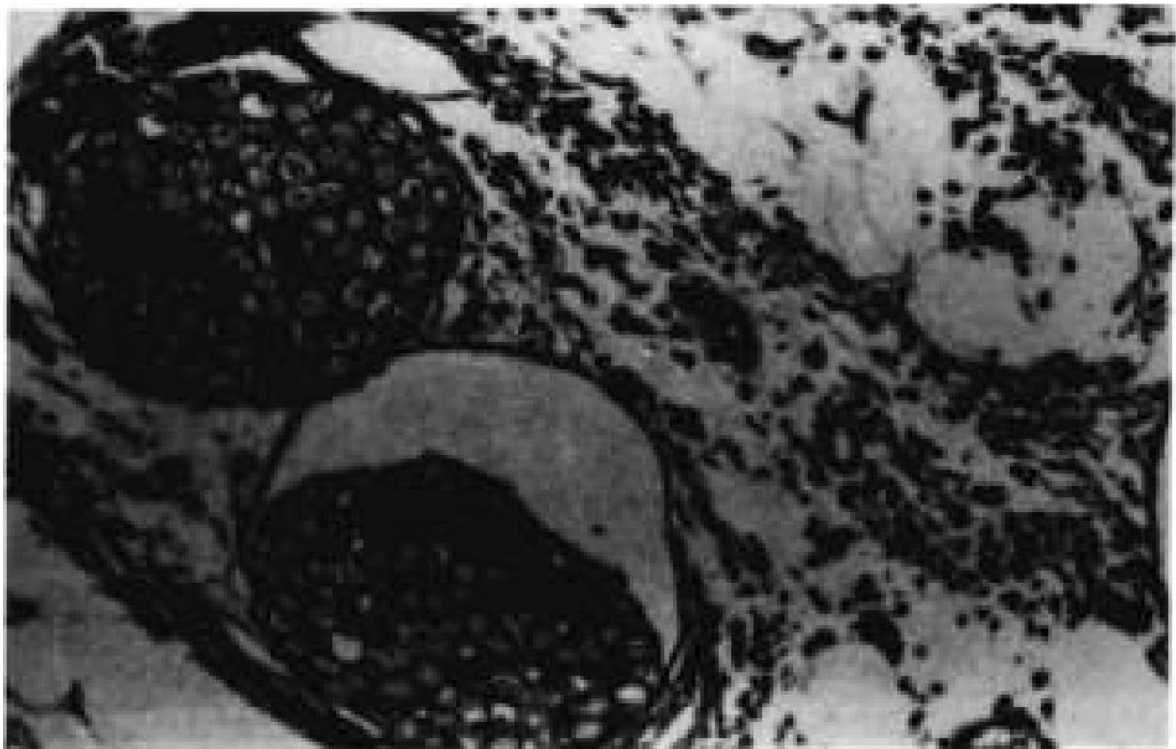


Figure 4. Lengthened nerve 1 month after distraction. (Masson's trichrome x300.)

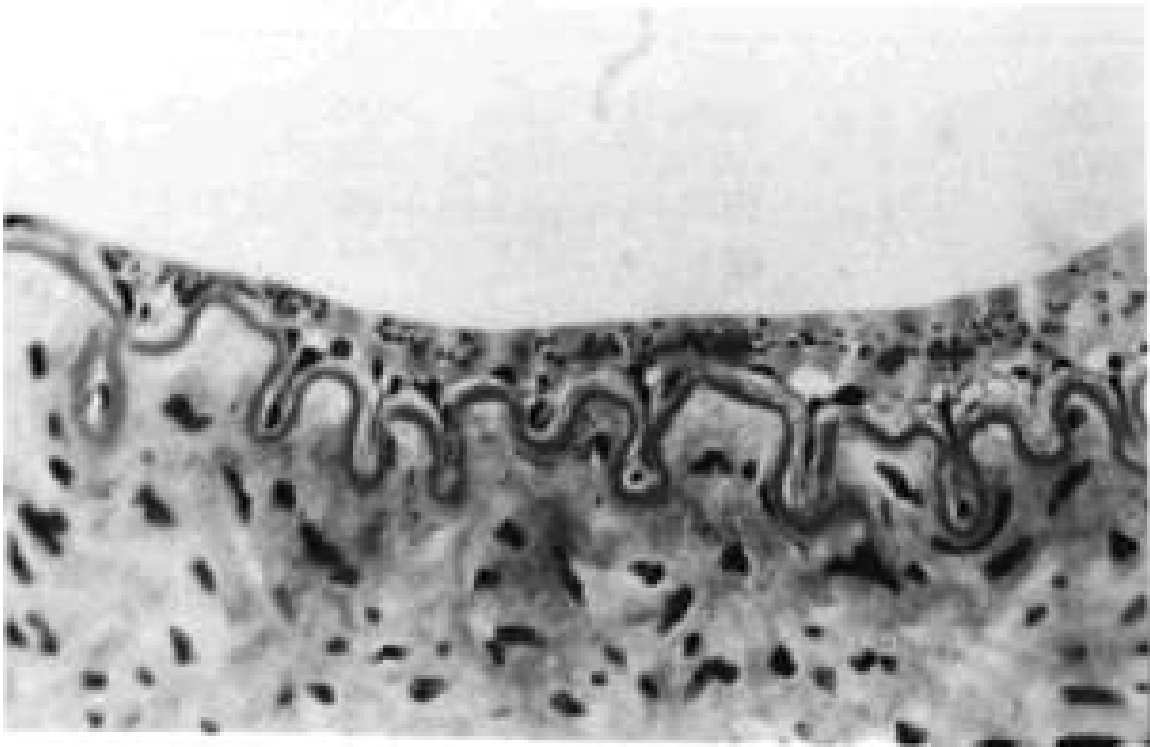


Figure 5. Lengthened posterior femoral artery showing hematic aggregates near endothelial cells. (Hematoxylin & eosin x1200, before 25% reduction.)

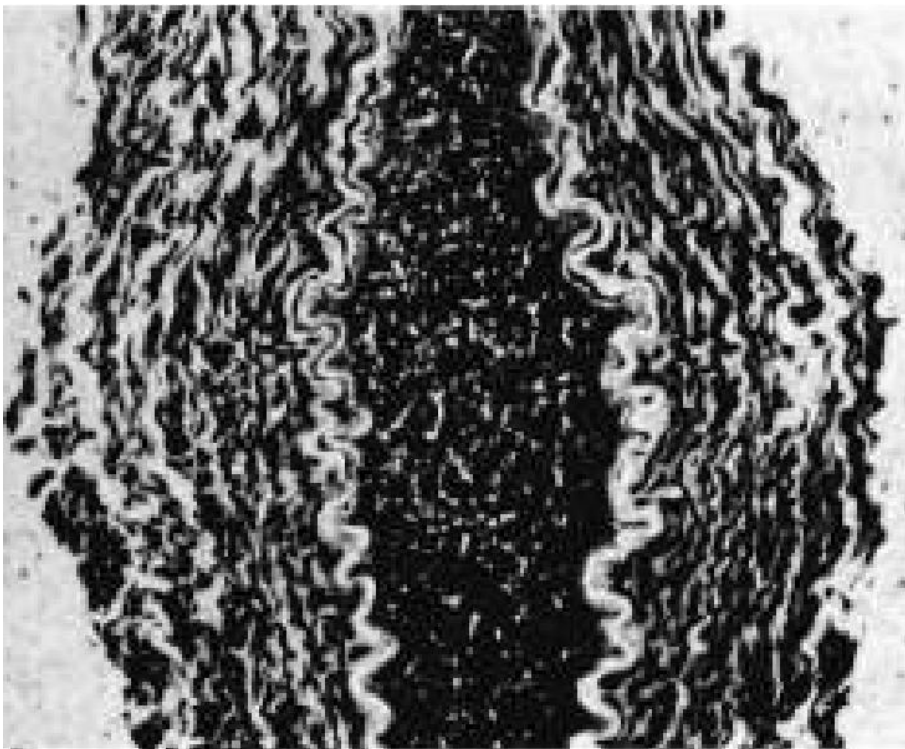


Figure 6. Lengthened posterior femoral vein showing thrombosis phenomena. (Masson's trichrome x800.)