Ultrasound Obstet Gynecol 2001; **17**: 434–438

Transvaginal color Doppler assessment of venous flow in adnexal masses

J. L. ALCÁZAR and G. LÓPEZ-GARCÍA

Department of Obstetrics and Gynecology, Clínica Universitaria de Navarra, School of Medicine, University of Navarra, Pamplona, Spain

KEYWORDS: Adnexal mass, Doppler ultrasound, Arterial flow, Venous flow

ABSTRACT

Objective *To analyze the usefulness of transvaginal color Doppler assessment of venous flow in the differential diagnosis of adnexal masses.*

Material and Methods *Ninety-one consecutive patients (mean age: 46.6 years, range: 16–81 years) diagnosed as having an adnexal mass were evaluated by transvaginal color Doppler sonography prior to surgery. Color Doppler was used to detect and analyze the flow velocity waveform from arterial and venous blood flow within the tumor. For arterial signals the resistance index and peak systolic velocity, and for veins the maximum venous flow velocity, were calculated. Receiver operator characteristic curves were plotted to determine the best venous flow velocity cut-off. According to our previous study using arterial Doppler, a tumor was considered as malignant when flow was detected and the lowest resistance index was ≤ 0.45. Using venous Doppler a mass was considered as malignant when flow was detected and the venous flow velocity was ≥ the best cut-off found on the receiver operator characteristic curve. Definitive histopathological diagnosis was obtained in all cases. Sensitivity, specificity, positive predictive value and negative predictive value for B-mode morphology (evaluation performed according to Sassone's scoring system), arterial Doppler, venous Doppler, and a combination of both arterial and venous Doppler were calculated.*

Results *Twenty-five masses (27.5%) were malignant and 66 (72.5%) benign. Arterial and venous flow was found more frequently in malignant than in benign masses (92% vs. 41% (P < 0.001) and 72% vs. 21% (P < 0.001), respectively). The resistance index was significantly lower in malignant tumors (0.42 vs. 0.60, P = 0.0003). No differences were found in peak systolic velocity. Venous flow velocity was significantly higher in malignant masses (18.1 cm/s vs. 8.9 cm/s, P = 0.0006). The best cut-off of venous flow velocity was 10 cm/s. Sensitivity, specificity, positive predictive value and negative predictive value for morphology, arterial Doppler, venous Doppler, and the combination of both arterial and venous Doppler were 92%, 71%, 45%, 96%; 76%, 95%, 87%, 91%; 68%, 94%, 81%, 89%; and 88%, 91%, 79%, 95%, respectively.*

Conclusions *Our results indicate that preoperative evaluation by venous flow assessment of adnexal masses may be useful to discriminate between malignant and benign tumors.*

INTRODUCTION

Since the introduction of transvaginal color Doppler sonography in the assessment of ovarian tumor vascularity[1], many studies concerning its usefulness to discriminate between malignant and benign adnexal masses have been reported. Although some authors have found this technique useful[2–10], others have questioned these results[11–17].

All these studies have focused on the evaluation of arterial blood flow in the adnexal mass, trying to find differences in blood flow impedance or arterial systolic velocity between benign and malignant tumors based on the vascular changes in malignant tumors due to neoangiogenesis[18].

However, to the best of our knowledge, no study has assessed the role of venous flow in the differential diagnosis of adnexal masses. The aim of this study was to evaluate venous flow in a series of adnexal masses and to determine whether it can be used to discriminate between malignant and benign tumors.

MATERIALS AND METHODS

From June 1998 to May 1999, 180 consecutive patients diagnosed as having an adnexal mass were evaluated by transvaginal color Doppler sonography in our institution. Ninety-one patients underwent surgical removal of the adnexal mass during this period. This report is based on these 91 patients.

Patients' age ranged from 16–81 years (mean age. 46.6 years, SD: 14.1). Fifty-eight (63.7%) were premenopausal and 33 (36.3%) were postmenopausal.

Correspondence: Dr J. L. Alcázar, Department of Obstetrics and Gynecology, Clínica Universitaria de Navarra, Avenida Pio XII, 36, 31008 Pamplona, Spain (e-mail: jlalcazar@unav.es)

Received 12-7-99, Revised 11-10-00, Accepted 8-2-01

All patients underwent transvaginal color Doppler sonography within 1 week prior to surgery. Ultrasonic examinations were performed using a Philips P700 SE machine (Philips Ultrasound, Santa Ana, CA, USA) with a real-time 6.5-MHz sector electronic array endovaginal probe with 5.0-MHz pulsed Doppler system and equipped with the color velocity imaging (CVI) system for color blood flow coding[19]. The system operates at power outputs of less than 80 mW/cm^2 in the B-mode, pulsed Doppler and CVI modes. The high-pass filter was set at 100 Hz and pulsed Doppler sample volume was set at 1.2–2 mm width. Pulse repetition frequency was set at 1.5–25 kHz.

Morphological evaluation of the adnexal masses was performed according to Sassone's scoring system[20]. Briefly, it evaluates wall thickness (score 1–3), the presence of septa and their thickness (score 1–3), inner wall structure (score 1–4), and echogenicity (score 1–5). A combined score of 4–15 is thus obtained. A score of ≥ 9 was considered as being suggestive of malignancy.

Tumor volume was calculated according to the prolate ellipse formula: length (cm) × height (cm) × width (cm) × 0.5233, and expressed in mL.

After morphologic evaluation, the CVI gate was activated to identify blood flow signals within the adnexal mass and pulsed Doppler was used to analyze each color signal detected. A flow velocity waveform (FVW) was obtained in each case. We identified arterial and venous signals. Arterial blood flow was characterized by a biphasic FVW with a systolic and a diastolic component (Figure 1), whereas venous flow was characterized by a monophasic continuous flow (Figure 2). From arterial signals blood flow impedance was estimated by calculating the resistance index (RI = (maximum systolic velocity – end diastolic velocity)/maximum systolic velocity) from three consecutive FVWs. The lowest RI found after every color spot had been interrogated was analyzed. Peak systolic velocity (PSV, cm/s) was also recorded in each vessel. From venous signals only maximum velocity was calculated, the venous flow velocity (VFV, cm/s). In those tumors with more than one venous vessel detected, that with the highest VFV was analyzed. No angle correction was made because the vessels studied were too small to allow this, although we always tried to obtain the highest Doppler shift to measure the velocity.

All ultrasound examinations were performed by one of the authors (J.L.A.). From a previous study we estimated an intraobserver coefficient of variation for RI and PSV of 6% and 12%, respectively[21]. The coefficient of variation for VFV and the number of venous vessels within a given tumor was calculated in the first 10 patients by performing two examinations with a 10-min interval between examinations. Color and pulsed Doppler evaluation was performed, measuring the number of vessels detected and VFV. The coefficient of variation for VFV and number of venous vessels were 8% and 4%, respectively.

All patients underwent surgical removal of the adnexal mass and definitive histopathological diagnosis was obtained in every case. Surgeons were blinded to the results of flow studies. Tumors were classified according to the World Health Organization[22]. Ovarian malignancies were staged according to the FIGO[23]. Low grade (borderline) malignant tumors were considered as malignant masses for statistical analysis.

The Kolmogorov–Smirnov test was used to determine normal distribution of continuous variables. Data were expressed as mean and standard deviation (SD) or median with interquartile range (IQR) where appropriate. One-way analysis of variance or Mann–Whitney *U*-tests were used to compare continuous variables, where appropriate. Fisher's exact test was used to compare categorical variables. All tests were two-tailed. Receiver operator characteristic (ROC) curves were plotted to determine the best cut-off of VFV and PSV to differentiate benign from malignant adnexal masses, and to confirm whether the pre-established RI cut-off was the best one. The area under the curve was calculated for each parameter.

Sensitivity, specificity, positive predictive value (PPV) and negative predictive value (NPV) for morphological scoring system (Morphology), arterial Doppler (AD), and venous Doppler (VD) were calculated. Sensitivity and specificity were compared using the McNemar test. We further calculated

Figure 1 Sonogram showing a characteristic arterial biphasic flow velocity waveform from an arterial vessel, with a systolic and a diastolic component, obtained from a left-sided cystic adnexal mass.

Figure 2 The same case as in Figure 1 showing a characteristic venous monophasic flow velocity waveform, with continuous flow, obtained from a venous vessel.

the sensitivity, specificity, PPV and NPV for a combination of arterial and venous flow (AVD), when arterial or venous Doppler suggested malignancy.

According to our previous study, arterial Doppler findings were considered as suggestive of malignancy when arterial flow was detected and the lowest RI found was ≤ 0.45[21]. Venous Doppler was considered as suggestive of malignancy when venous flow was detected and the highest VFV found was ≥ to the best cut-off found on the ROC curve.

The 95% confidence intervals were calculated where appropriate.

A *P*-value of < 0.05 was considered as statistically significant.

All statistical analyses were performed using the SPSS (Statistical package for the Social Sciences) version 6.0 for Windows (SPSS Inc., Chicago, IL, USA).

RESULTS

Twenty-five (27.5%) masses were found to be malignant and 66 (72.5%) were benign (Table 1). Stages of primary ovarian malignancies were as follows: stage I: five (23%); stage III: 13 (59%) and stage IV: four (18%).

Arterial blood flow was found in 92% (23/25) of malignant tumors as compared with 41% (27/66) of benign tumors ($P < 0.001$). Venous flow was found in 72% (18/25) of malignant masses, whereas it was found in 21% (14/66) of benign masses ($P < 0.001$).

Median tumor volume in malignant masses (267.9 mL, IQR: 498.1) was significantly higher than in benign tumors (63.7 mL, IQR: 145.5, $P = 0.012$),

Venous flow velocity was significantly higher in malignant tumors. No differences were found in PSV (Table 2). The numbers of arterial and venous vessels were significantly higher in malignant tumors (Table 2).

In malignant masses, mean RI and mean score were significantly lower and higher, respectively, than in benign tumors (Table 2).

Receiver operator characteristic curve analysis revealed that the best VFV cut-off was 10 cm/s, with a sensitivity of 94% and specificity of 71%(Figure 3).

Sensitivity and specificity for morphology, AD, VD and AVD are shown in Table 3. Both AD and VD had similar performance. However, both techniques had significantly higher specificity than morphology, but morphology was more sensitive. Combined AVD had increased sensitivity with no decrease in specificity; the combination had similar sensitivity but significantly higher specificity than morphology alone.

Table 1 Histopathologic diagnosis in 91 adnexal masses

Histology	n	%
Endometrioma	16	17.6
Serous cystadenoma	14	15.4
Mature teratoma	9	9.9
Mucinous cystadenoma	4	4.4
Cystadenofibroma	5	5.5
Paraovarian cyst	3	3.3
Fibrothecoma	3	3.3
Follicular cyst	2	2.2
Hemorrhagic cyst	3	3.3
Hydrosalpinx	1	1.1
Mesotelial cyst	1	1.1
Tubo-ovarian abscess	2	2.2
Struma ovarii	2	2.2
Leiomyoma	1	1.1
Low malignant potential tumors	2	2.2
Primary cystadenocarcinoma	20	22.0
Metastatic carcinoma	3	3.3

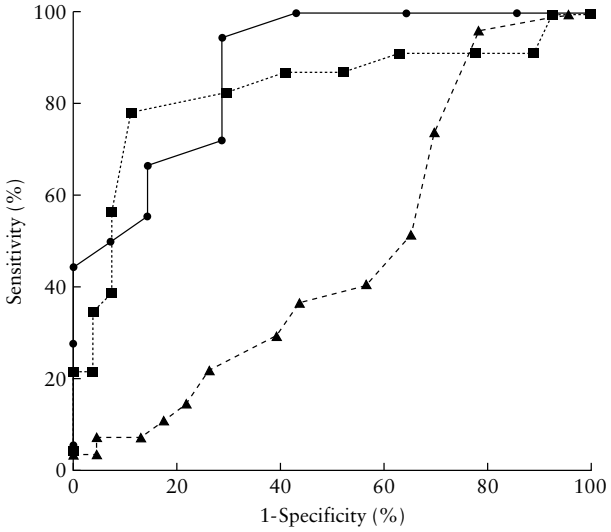

Figure 3 Receiver operator characteristic curves for venous flow velocity (●, area under the curve: 0.859; standard error: 0.06), peak systolic velocity (▲, area under the curve: 0.512; standard error: 0.09) and lowest resistance index (■, area under the curve: 0.828; standard error: 0.06).

Table 2 Sonographic and Doppler parameters in malignant and benign masses

	Benign	*Malignant*	P-*value*
Sassone's score	6.9 (2.5)	10.9 (1.7)	< 0.0001
Lowest RI	0.60 (0.1)	0.42 (1.7)	0.0003
PSV (cm/s)	29.1 (22.2)	31.2 (22.9)	0.745
VFV (cm/s)	8.9 (8.9)	18.1 (9.5)	0.0006
Number of arterial vessels	0.55 (0.2)	2.3 (1.7)	< 0.001
Number of venous vessels	1.5 (1.2)	3.1 (1.2)	< 0.001

Data expressed as means (standard deviations in parentheses). RI, resistance index; PSV, peak systolic velocity; VFV, venous flow velocity.

Table 3 Sensitivity and specificity for morphology, arterial Doppler, venous Doppler and combined arterial and venous Doppler

	*Sensitivity (%)**	*Specificity (%)†*
Morphology[a]	92.0 (74.9–99.6)	71.2 (58.7–81.7)
Arterial Doppler[b]	76.0 (54.9–90.6)	95.5 (87.3–99.0)
Venous Doppler[c]	68.0 (46.5–85)	93.9 (85.2–98.3)
Arterial and venous Doppler[d]	88.0 (68.8–97.1)	90.9 (81.2–96.6)

95% confidence intervals in parentheses; *a vs. b: $P < 0.0001$; a vs. c: $P < 0.0001$; a vs. d: P = NS; b vs. c: P = NS; b vs. d: $P = 0.031$; c vs. d: $P = 0.016$; †a vs. b: $P < 0.0001$; a vs. c: $P < 0.0001$; a vs. d: $P < 0.0001$; b vs. c: P = NS; b vs. d: P = NS; c vs. d: P = NS; NS, not significant.

The PPVs and NPVs for morphology, AD, VD and AVD were: 45% and 96%; 87% and 91%; 81% and 89%; 79% and 95%, respectively.

DISCUSSION

Transvaginal color Doppler assessment of adnexal masses was used in an attempt to improve the diagnostic accuracy of ultrasound in determining the nature, benign or malignant, of these masses. The rationale for using this technique was based on the fact that Doppler allows the assessment of angiogenesis *in vivo* as demonstrated by Ramos *et al.*[24] and Dock *et al.*[25]. Angiogenesis is an essential event in malignant tumor growth in which new vessels are formed within the tumor allowing the supply of oxygen and nutrients to tumoral cells. This new vascular network consists of venulae, capillaries and arteriovenous shunts. The neovascularized arterioles are characterized by a paucity or absence of the muscular media. These vascular changes can be detected by Doppler, showing a significant decreased impedance to flow distal to the point of measurement[26].

Since the pioneering report of Kurjak and coworkers[1], many studies have been published in recent years assessing the value of transvaginal color Doppler to differentiate between malignant and benign adnexal masses. The results have been controversial. Some authors have found this technique useful[2–10], whereas others have not[11–17]. Some factors put forward to explain these conflicting results include differences in sonographers' experience, different sensitivity in ultrasound machines and the lack of standarization of Doppler measurements[27]. All these studies have focused only on arterial vessels assessing blood flow impedance, by calculating two angle-independent indices of FVW spectral analysis (RI and PI) and the PSV. This simple assessment of arterial flow might also help to explain these controversial results. Thus, more complex multiparameter analysis[28], scoring systems[29] and logistic models[30] have been proposed.

To the best of our knowledge, however, no study has analyzed the role of venous blood flow in discriminating between malignant and benign adnexal masses. Our results indicate that malignant tumors show venous vessels in a higher percentage of cases than do benign tumors. We also found that VFV was significantly higher in malignant than in benign masses.

Diagnostic performance of venous flow assessment was similar to that of arterial flow, and more specific but also significantly less sensitive than morphologic evaluation.

Doppler was significantly more specific than morphologic evaluation with comparable sensitivity, when an adnexal mass was considered as suggestive of malignancy when arterial flow was found and the lowest RI was ≤ 0.45 or when venous flow was present and flow velocity was ≥ 10 cm/s. Notwithstanding, we think that morphologic assessment should remain the major diagnostic criterion in sonographic evaluation of adnexal masses, due to its high sensitivity, with Doppler assessment an adjuvant tool to reduce the false-positive rate.

These results indicate that the addition of venous flow assessment to conventional arterial evaluation may increase the diagnostic performance of Doppler ultrasound in the differentiation of malignant from benign adnexal masses. Venous flow assessment is simple, since it involves evaluation of only one parameter. Furthermore, VFV estimation seemed to be reproducible.

In conclusion, we have evaluated the role of transvaginal color Doppler assessment of venous flow in adnexal masses. Our results indicate that malignant tumors are characterized by higher venous blood flow velocities than benign tumors and that measurement of VFV may be used for discriminating between benign and malignant adnexal masses. This should, however, be cross-validated prospectively.

REFERENCES

1 Kurjak A, Zalud I, Jurkovic D, Alfirevic Z, Miljan M. Transvaginal color Doppler for the assessment of pelvic circulation. *Acta Obstet Gynecol Scand* 1989; 68: 131–5

2 Kurjak A, Zalud I, Alfirevic Z. Evaluation of adnexal masses with transvaginal color Doppler. *J Ultrasound Med* 1991; 10: 295–7

3 Weiner Z, Thaler I, Beck D, Rottem S, Deutsch M, Brandes JM. Differentiating malignant from benign ovarian tumors with transvaginal color flow imaging. *Obstet Gynecol* 1992; 79: 159–62

4 Kawai M, Kano T, Kikkiawa F, Maeda O, Oguchi H, Tomoda Y. Transvaginal Doppler ultrasound with color flow imaging in the diagnosis of ovarian cancer. *Obstet Gynecol* 1992; 79: 163–7

5 Kawai M, Kikkawa F, Ishikawa H, Tamakoshi K, Maeda O, Hasegawa N, Mizuno K, Suzuki A, Itakura A, Nakashima N, Tomoda Y. Differential diagnosis of ovarian tumors by transvaginal color-pulsed Doppler sonography. *Gynecol Oncol* 1994; 54: 209–14

6 Tepper R, Lerner-Geva L, Altaras MM, Goldberger S, Ben-Baruch G, Markov S, Cohen I, Beyth Y. Transvaginal color flow imaging in the diagnosis of ovarian tumors. *J Ultrasound Med* 1995; 14: 731–4

7 Zanetta G, Vergani P, Lissoni A. Color Doppler ultrasound in the preoperative assessment of adnexal masses. *Acta Obstet Gynecol Scand* 1994; 73: 637–40

8 Strigini FA, Gadducci A, Del Bravo B, Federghini M, Genazzani AR. Differential diagnosis of adnexal masses with transvaginal sonography, color flow imaging and serum CA-125 assay in pre- and postmenopausal women. *Gynecol Oncol* 1996; 61: 68–72

9 Predanic M, Vlahos N, Pennisi JA, Moukhtar M, Aleem FA. Color and pulsed Doppler sonography, gray-scale imaging and serum CA-125 in the assessment of adnexal disease. *Obstet Gynecol* 1996; 88: 283–9

10 Leeners B, Schild R, Funk A, Hauptmann S, Kemp B, Schröder W, Rath W. Colour Doppler improves the pre-operative diagnosis of ovarian tumours made using transvaginal sonography. *Eur J Obstet Gynecol Reprod Biol* 1996; 64: 79–85

11 Hata K, Hata T, Manabe A, Sugimura K, Kitao M. A critical evaluation of transvaginal Doppler studies, transvaginal sonography, magnetic resonance imaging and CA-125 in detecting ovarian cancer. *Obstet Gynecol* 1992; 80: 922–6

12 Tekay A, Jouppila P. Validity of pulsatility and resistance indices in classification of adnexal tumors with transvaginal color Doppler ultrasound. *Ultrasound Obstet Gynecol* 1992; 2: 338–44

13 Hamper UM, Sheth S, Abbas FM, Rosenshein NB, Aronson D, Kurman RJ. Transvaginal color Doppler sonography of adnexal masses: Differences in blood flow impedance in benign and malignant lesions. *AJR Am J Roentgenol* 1993; 160: 1225–8

14 Valentin L, Sladkevicius P, Marsal K. Limited contribution of Doppler velocimetry to the differential diagnosis of extrauterine pelvic tumors. *Obstet Gynecol* 1994; 83: 425–33

15 Bromley B, Goodman H, Benacerraf BR. Comparison between sonographic morphology and Doppler waveform for the diagnosis of ovarian malignancy. *Obstet Gynecol* 1994; 83: 434–7

16 Roman LD, Muderspach LI, Stein SM, Laifer-Marin S, Groshen S, Morrow CP. Pelvic examination, tumor marker level and gray-scale and Doppler sonography in the prediction of pelvic cancer. *Obstet Gynecol* 1997; 89: 493–500
17 Kustnezoff D, Gnochi D, Damonte C, Sananes C, Giaroli A, Di Paola G, Sardi JE. Differential diagnosis of pelvic masses: Usefulness of CA-125, transvaginal sonography and echo-Doppler. *Int J Gynecol Cancer* 1998; 8: 315–21
18 Folkman J. Angiogenesis in cancer, vascular, rheumatoid and other disease. *Nat Med* 1995; 1: 27–31
19 Alcázar JL, Laparte C. In vivo validation of time-domain velocity measurement technique of blood flow in human fetuses. *Ultrasound Med Biol* 1998; 24: 9–13
20 Sassone AM, Timor-Tritsch IE, Artner A, Westhoff C, Warren WB. Transvaginal sonographic characterization of ovarian disease: Evaluation of a new scoring system to predict ovarian malignancy. *Obstet Gynecol* 1991; 78: 70–6
21 Alcázar JL, Ruiz-Perez ML, Errasti T. Transvaginal color Doppler sonography in adnexal masses: Which parameter performs best? *Ultrasound Obstet Gynecol* 1996; 8: 114–9
22 Serov SF, Scully RE, Sobin LH. *International histological classification of tumors. No 9, Histological Typing of Ovarian Tumors*. Geneva: World Health Organization, 1973
23 Sheperd JH. Revised FIGO staging for gynaecological cancer. *Br J Obstet Gynaecol* 1989; 96: 889–92
24 Ramos I, Fernandez LA, Morse SS, Fortune KL, Taylor KJ. Detection of neovascular signals in a 3 day Walker 256 rat carcinoma by Doppler ultrasound. *Ultrasound Med Biol* 1988; 14: 123–6
25 Dock W, Grabenwoger F, Metz V, Eibenberger K, Farres MT. Tumor vascularization: assessment with duplex sonography. *Radiology* 1991; 181: 241–4
26 Kurjak A, Predanic M, Kupesic-Urek S, Jukic S. Transvaginal color and pulsed Doppler assessment of adnexal tumor vascularity. *Gynecol Oncol* 1993; 50: 3–9
27 Kurjak A, Kupesic S. Transvaginal color Doppler and pelvic tumor vascularity: lessions learned and future challenges. *Ultrasound Obstet Gynecol* 1995; 6: 145–59
28 Fleischer AC, Rodgers WH, Keppler DM, Williams LL, Jones III HW. Color Doppler sonography of ovarian masses: a multiparameter analysis. *J Ultrasound Med* 1993; 12: 41–8
29 Kurjak A, Predanic M. New scoring system for prediction of ovarian malignancy based on transvaginal color Doppler sonography. *J Ultrasound Med* 1992; 11: 631–8
30 Alcázar JL, Jurado M. Using a logistic model to predict malignancy of adnexal masses based on menopausal status, ultrasound morphology and color Doppler findings. *Gynecol Oncol* 1998; 69: 146–50